

Case report

Transient visual field loss after COVID-19 vaccination: Experienced by ophthalmologist, case report

Chaisiri Jumroendararasame^{a,*}, Somboon Panyakorn^a, Rittirak Othong^b,
Auraya Jumroendararasame^c, Worapot Srimanan^a, Kun Tipparut^a

^a Department of Ophthalmology, Phramongkutklao Hospital, Bangkok, Thailand

^b Medical Toxicology Unit, Department of Emergency Medicine, Faculty of Medicine Vajira Hospital, Navamindradhiraj University, Bangkok, Thailand

^c Department of Ophthalmology, Bangkok Metropolitan Administration General Hospital, Bangkok, Thailand

ARTICLE INFO

Keywords:

Visual field defect
COVID-19 vaccine
CoronaVac
Sinovac
Case report

ABSTRACT

Purpose: The first reported case of bilateral transient visual field defect, experienced by an ophthalmologist, which developed shortly after COVID-19 vaccination (CoronaVac, Sinovac Biotech Ltd., Beijing, China) and confirmed by computerized automated perimetry.

Observation: The patient is a 42-year-old Thai ophthalmologist. He developed blurred vision within an hour after the second dose of COVID-19 vaccination. We described his self-observed of sequential symptoms, chronologic events, and management steps. The visual field of left congruous hemianopia with respect to vertical midline was detected with computerized automated perimetry. The possible mechanism could be related to an acute vasospasm of the artery in the postchiasmatic visual pathway, triggered by COVID-19 vaccine, Corona Vac.

Conclusion and importance: With increasing use of the COVID-19 vaccine in the near future, it would be prudent for medical staff and ophthalmologists to be considered and aware of this associated condition.

1. Introduction

Since the global spreading of the Severe Acute Respiratory Syndrome Coronavirus 2 (SARS-CoV-2) in December 2019, the situation has worsened, resulted in the pandemic declaration by the World Health Organization (WHO) on March 11th, 2020.¹ The expedited development and approval of Covid-19 vaccine is an inevitable solution. Many possible side effects of the Covid-19 vaccine have been reported including fever, pain, weakness and paralysis.² Vision related adverse effects can be found and had been reported after other vaccination such as influenza,³ measles, rubella,⁴ rabies,⁵ tuberculosis,⁶ hepatitis B,⁷ meningitis,⁸ anthrax⁹ and tetanus¹⁰ vaccine. However, to the best of our knowledge, there was no report of visual field defect, developed shortly after COVID-19 vaccination (CoronaVac, Sinovac Biotech Ltd., Beijing, China) which was occurred and had been self-detected by an ophthalmologist (CJ).

2. Case report

A 42-year-old Thai male ophthalmologist (CJ), otherwise healthy with a history of good controlled dyslipidemia for 10 years, using Rosuvastatin 20 mg. daily. He received the first dose of Corona Vac (Sinovac Biotech Ltd., lot number A2021010041) on March 24th, 2021 without serious adverse reactions, only mild muscle sore of the injection site at left deltoid muscle. The second dose of Coronac Vac (lot number J202103002) was injected on April 21, 2021. He developed blurred vision within an hour after vaccination. Sequential symptoms, chronologic events, and management steps were described as followed. At 12.50 p.m., the patient had vaccination, and was closely observed in a designated area of the hospital for 30 minutes without any adverse events. Ten minutes later he noticed having a blurred vision starting at the center of his visual field, foggy in character. Scotoma enlarged within a couple of minutes before it obscured the left side of his visual field. He reported as looking through the watery scene but it was not dark. There was no associated headache or any weakness. The patient went back to the ophthalmology department 10 minutes after he had the

* Corresponding author. Department of Ophthalmology, Phramongkutklao hospital 315 Ratchavithi road, Thungphayathai sub-district, Ratchadevhi district, Bangkok, 10400, Thailand.

E-mail address: drbeachy@yahoo.com (C. Jumroendararasame).

<https://doi.org/10.1016/j.ajoc.2021.101212>

Received 11 June 2021; Received in revised form 18 July 2021; Accepted 20 September 2021

Available online 23 September 2021

2451-9936/© 2021 The Authors.

Published by Elsevier Inc.

This is an open access article under the CC BY-NC-ND license

(<http://creativecommons.org/licenses/by-nc-nd/4.0/>).

abnormal vision seeking for an urgent care. The eye examination revealed visual acuity of 20/20 in both eyes, with unremarkable anterior segment, and normal fundus. Neither intra-ocular inflammation nor relative afferent pupillary defect (RAPD) was detected. Optical coherent tomography (OCT) of the macula was normal. He also undergone visual field test with computerized automated perimetry (CTVF, Humphrey HFA II-I 750i field analyzer, Carl Zeiss Meditec, INC, Dublin, CA, USA) program 24-2 fast and the results were as shown in Fig. 1.

Stroke fast track then was initiated at 50 minutes after having the blurred vision. Neurological examination was done by neurologists which was unremarkable. At the time, the only remarkable physical examination was his blood pressure (BP) which was found to be mildly elevated at 150/90 mmHg. (his baseline BP: 120/80 mmHg.). Regardless of normal neurological examination, MRI of brain was initiated 20 minutes later, result as in Fig. 3. In the meantime, the patient started to have a better vision but still not normal. After the completion of the MRI (2 hours after having the event), the patient reported normalization of his vision and visual field. CTVF was repeated about 2 hours 35 minutes post event, and it became normal, results as shown in Fig. 2. The patient was admitted to the hospital for intravenous fluid and oral aspirin (325mg.). Extensive investigations had been performed including normal CBC, FBS 86 mg/dL, HbA1C 5.6%, normal BUN/Cr, eGFR 103.58 mL/min/1.73 m², cholesterol 124 mg/dL, triglyceride 101.6 mg/dL, HDL-cholesterol 49 mg/dL, LDL-cholesterol 63.7 mg/dL, normal liver function test (AST 27.1 U/L & ALT 25 U/L), normal electrolytes, PT 10.70 seconds (INR 0.86), APTT 25.9 seconds (APTT ratio 0.98), TT 10.5 seconds (TT ratio 0.95), D-dimer 0.9 µg microgram/mL, fibrinogen 318 mg%. No other sequels were detected during the hospital stay, and no recurrence of symptoms, and other abnormalities during two months after the second dose of the CoronaVac injection.

3. Discussion and conclusion

After a vast number of the COVID-19 vaccines were distributed worldwide, we continue to see many emerging reports regarding the adverse drug reactions of these vaccines including pain at the injection site, swelling, fever, headache, fatigue, chills, muscle pain, nausea, diarrhea, rashes and swollen lymph nodes. The chance of any of these adverse effects were different and depend on a specific COVID-19 vaccine. Most of the effects were mild and temporary, however more serious adverse events have been increasingly reported such as the six cases of serious cerebral venous sinus thrombosis after receiving the Johnson & Johnson vaccine which causing the pause of their uses on April 13, 2021 by the CDC.¹¹

To date and the best of our knowledge, this is the first case report of transient visual field defect after the COVID-19 vaccination (CoronaVac), self-observed by an ophthalmologist and confirmed by the computerized automated perimetry. Many possible mechanisms could explain the cause of this transient bilateral hemianopic visual field defect. The most likely mechanism that we postulated would be related to an acute vasospasm of the artery in the postchiasmatic visual pathway, triggered by COVID-19 immunization. Right occipital lobe is the most likely affected area, characterized by congruous visual field defect with macular sparing,¹² and no other neurological abnormalities. The possible affected vessels would be small branches of middle¹³ or posterior¹⁴ cerebral arteries. The normal results on the brain MRI in our case, help excluding other structural abnormalities. Complete recovery of the visual function and visual field at roughly 1–2 hours in our case, suggested the reperfusion of affected arterial system. The differential diagnosis may include the reversible cerebral vasoconstriction syndrome (RCVS),¹⁵ cerebral venous sinus thrombosis (CVST),¹⁶ retinal migraine,¹⁷ optic neuritis,¹⁸ multiple evanescent white dot syndrome (MEWDS),¹⁹ and acute idiopathic blind spot enlargement syndrome (AIBSES),²⁰ which would be different in many aspects as the following.

RCVS is a rare condition of sudden constriction of cerebral vasculatures and generally not associated with viral infection but was recently

reported to be associated with COVID-19 infection.¹⁹ It is usually associated with an excruciating headache which tends to occur and reaches its peak intensity within seconds. The absence of headache is a rare exception.^{15,21} The brain MRI would have revealed abnormalities such as vasogenic edema, sulcal hyperintensity, intraparenchymal hemorrhage or infarction.²² The resolution of RCVS components usually takes days to weeks.¹⁵ Absence of severe headache, normal brain MRI, and rapid recovery of our case may not fit with this condition. Migraine is a common disabling brain disorder. Headache is a key marker and usually occurs during the course of visual disturbance.¹⁷ Repeated episode is needed before making diagnosis of this condition. Solitary visual disturbance in our case would be classified as retinal migraine which usually has an attack only on one eye, or typical migraine with aura but single episode of this bilateral visual field defects without headache makes this condition less likely. CVST is the condition with presence of blood clot in cerebral vein or dural venous sinuses. Symptoms include severe headache, visual disturbance or visual field defect or weakness.¹⁶ The diagnosis can be made by computerized tomography (CT) or MRI to demonstrate an obstruction of the venous sinus which is absent in our case. Optic neuritis has been reported to be associated with vaccination, most cases are bilateral which may involve the anterior segment or retrobulbar area.^{18,23} It usually develops within a week to a month after vaccination but could be earlier as in the first 24 hours,^{3–8,10} but the findings of visual field test did not fit with our case. MEWDS has been reported following influenza vaccination.²⁴ Patients usually have symptoms of unilateral blurred vision, photopsia, scotomas and purple hue of the vision. Spontaneous recovery would occur in a range of several weeks.¹⁹ By its characteristics, fundus findings, and laterality do not fit with our patient. AIBSES is a rare condition, and currently believed to be in a spectrum of primary inflammatory choriocapillariopathy (PICCP).²⁵ This condition has been reported following influenza vaccination. The patient could present with acute monocular scotoma, with otherwise normal fundus.²⁰ OCT may show a loss or irregularity of the ellipsoid layer in corresponding area of visual field defect.²⁶ An enlarged blind spot can only be the sole detected finding, which may resemble to temporal field defect, and mis-interpret if not respect to the midline but our patient had bilateral left hemianopic field with normal macular scan.

By conclusion, we report the first case of transient bilateral visual field defect characteristic of posterior visual pathway, triggered by COVID-19 vaccination. We postulate the possible mechanism would be from acute arterial vasospasm of corresponding branches of middle or posterior cerebral arteries. With increasing use of the COVID-19 vaccine in the near future, it would be prudent for medical staff and ophthalmologists to consider, and be aware of this associated condition.

Patient consent

Consent has been obtained from the patient.

Funding

No funding support

Author contribution

Conduct of the study (CJ).
Wrote and correct the manuscript (CJ, SP, AJ).
Collecting data Drafting the manuscript (AJ, WS, RO, KT).
All authors reviewed the manuscript.

Authorship

All authors attest that they met the current ICMJE criteria.

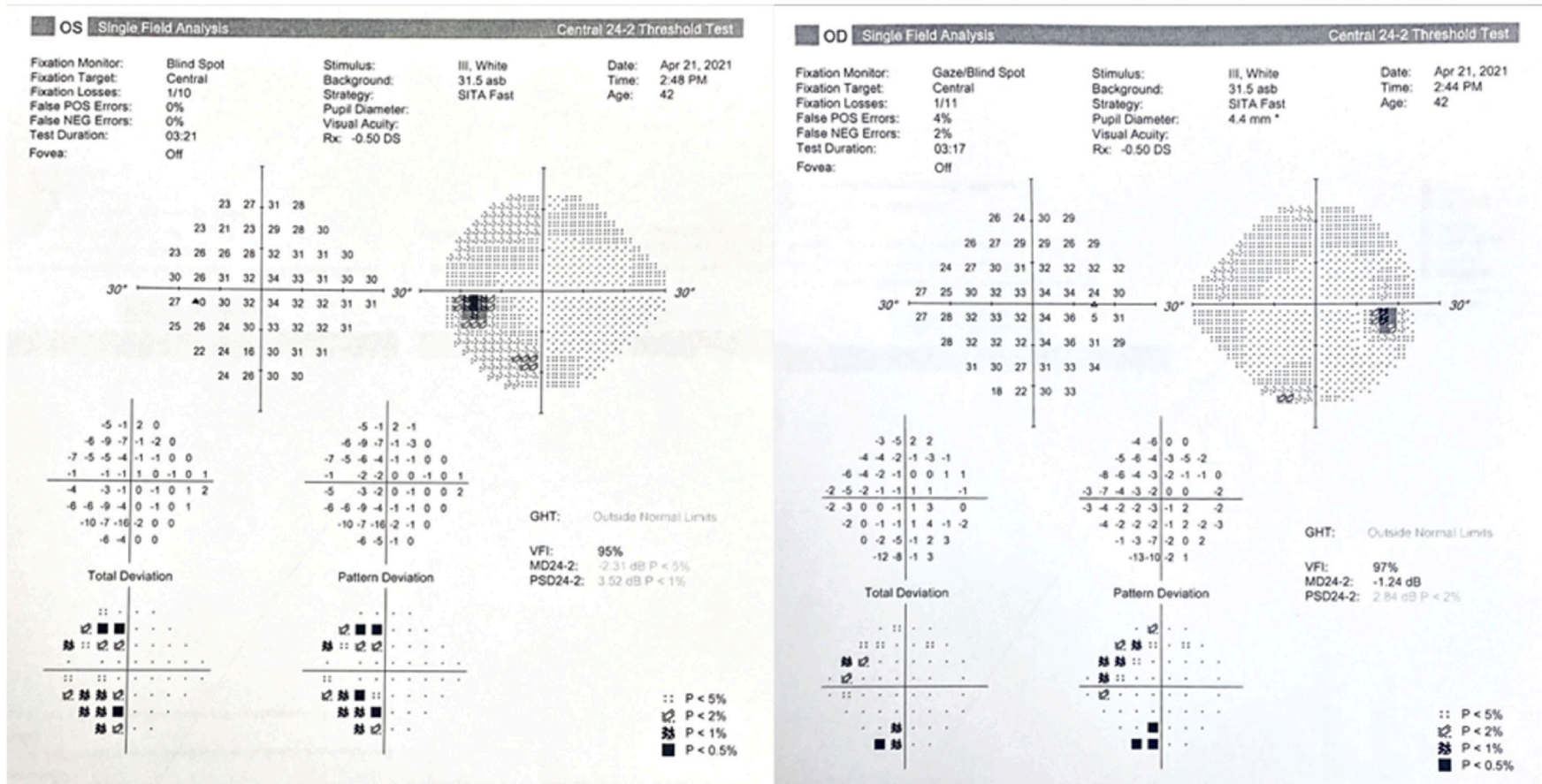


Fig. 1. Computerized visual field (CTVF) report programmed at 24-2 fast, obtained during an episode of visual field loss, showed left congruous hemianopia with respect to vertical midline.

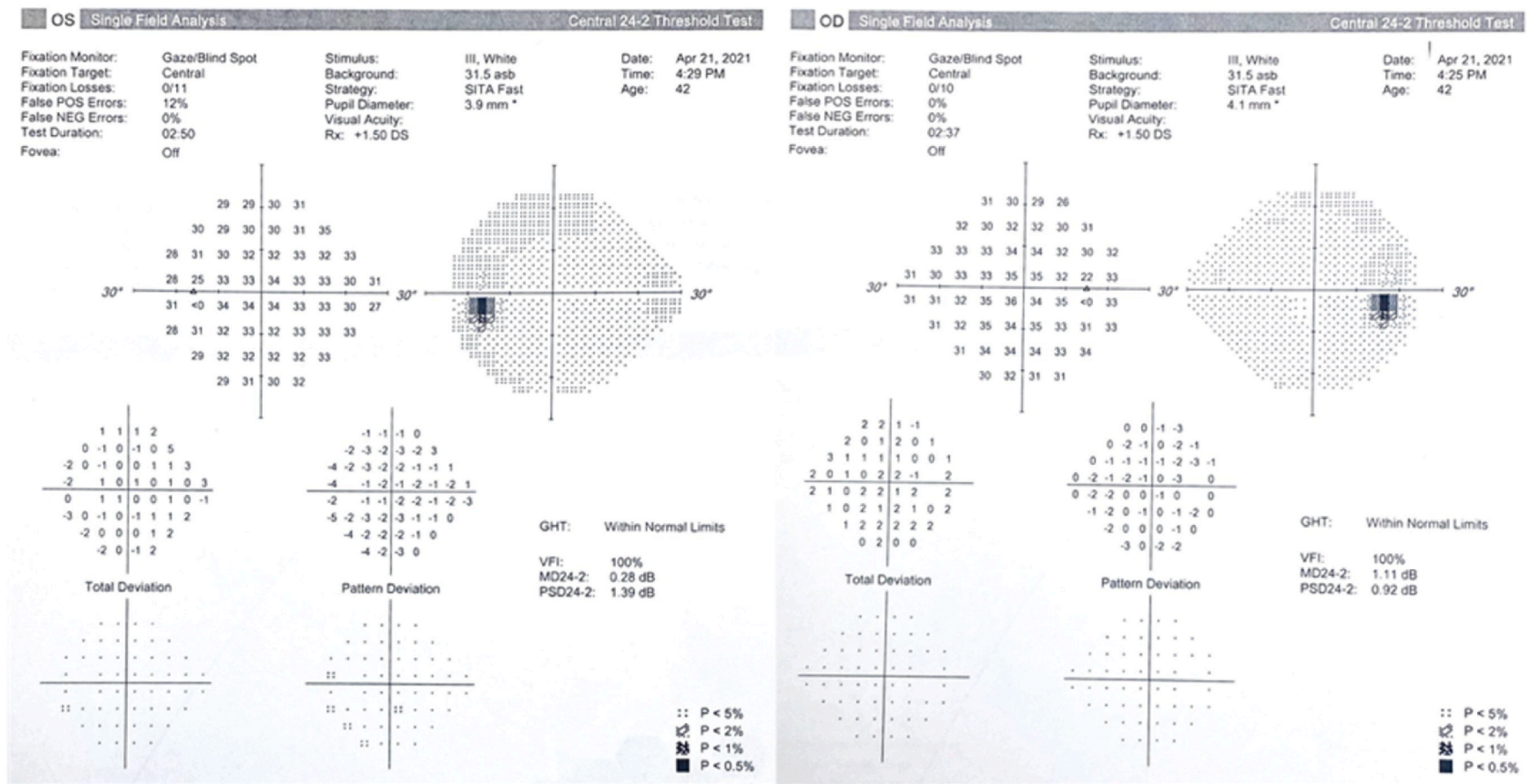


Fig. 2. CTVF report programmed at 24-2 fast, obtained after an improvement of vision 2 hours later, showed normalization of the previous visual field defect.

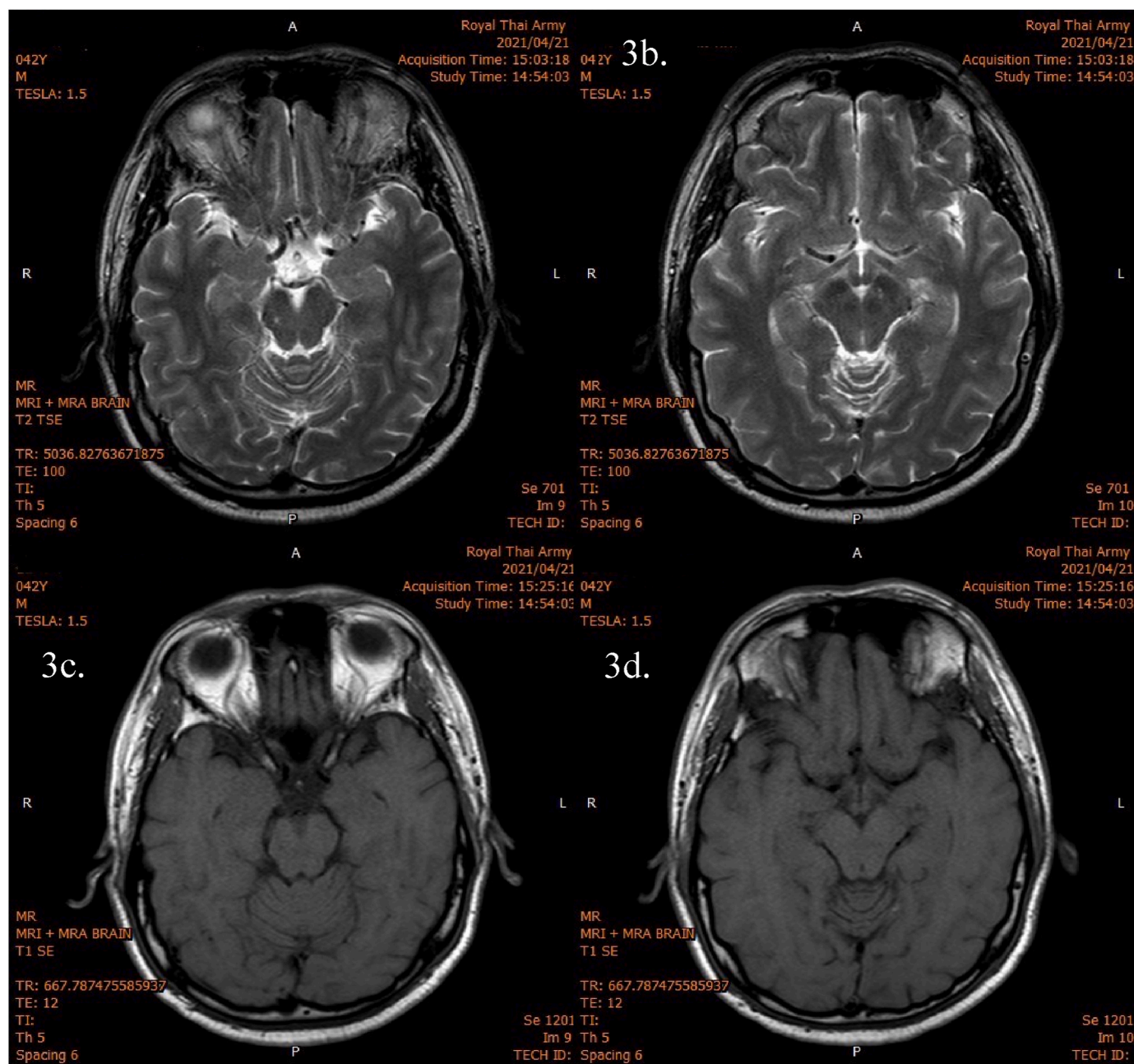


Fig. 3. MRI brain imaging (diffusion-weighted imaging, DWI) showed no evidence of acute intracranial infarction, hemorrhage, significant stenosis, arteriovenous malformation (AVM) or aneurysm. There is a suspicion of an old lacunar infarction at right cerebral peduncle.

Research ethics

Written consent to publish potentially identifying information, such as details or the case and photographs, was obtained from the patient(s) or their legal guardian(s).

Declaration of competing interest

The following authors have no financial disclosures: (CJ, SP, RO, AJ, WS, KT).

Acknowledgement

Dr. Chaisiri Jumroendarasame had full access to all the data in this study and take responsibility for the integrity and the accuracy of the

data.

References

1. WHO Remarks at the Media Briefing on COVID-19 - 11 March 2020. Who.int; 2021. <https://www.who.int/director-general/speeches/detail/who-director-general-s-opening-remarks-at-the-media-briefing-on-covid-19-11-march-2020>. Accessed May 16, 2021. Accessed.
2. Haidere MF, Ratan ZA, Nowroz S, et al. COVID-19 vaccine: critical questions with complicated answers. *Biomol Ther.* 2021;29(1):1–10. <https://doi.org/10.4062/biomolther.2020.178>.
3. Hull TP, Bates JH. Optic neuritis after influenza vaccination. *Am J Ophthalmol.* 1997; 124(5):703–704. [https://doi.org/10.1016/S0002-9394\(14\)70918-3](https://doi.org/10.1016/S0002-9394(14)70918-3).
4. Kazarian EL, Gager WE. Optic neuritis complicating measles, mumps, and rubella vaccination. *Am J Ophthalmol.* 1978;86(4):544–547. [https://doi.org/10.1016/0002-9394\(78\)90304-5](https://doi.org/10.1016/0002-9394(78)90304-5).
5. Gupta V, Bandyopadhyay S, Bapuraj JR, Gupta A. Bilateral optic neuritis complicating rabies vaccination. *Retina Phila Pa.* 2004;24(1):179–181. <https://doi.org/10.1097/00006982-200402000-00033>.

6. Hegde V, Dean F. Bilateral panuveitis and optic neuritis following Bacillus Calmette-Guérin (BCG) vaccination. *Acta Paediatr Oslo Nor* 1992. 2005;94(5):635–636. <https://doi.org/10.1111/j.1651-2227.2005.tb01954.x>.
7. Albitar S, Bourgeon B, Genin R, et al. Bilateral retrobulbar optic neuritis with hepatitis B vaccination. *Nephrol Dial Transplant Off Publ Eur Dial Transpl Assoc - Eur Ren Assoc*. 1997;12(10):2169–2170. <https://doi.org/10.1093/ndt/12.10.2169>.
8. Laria C, Alió J, Rodríguez JL, Galal A. Optic neuritis after meningococcal vaccination. *Arch Soc Esp Oftalmol*. 2006;81:479–482.
9. Nass M. Nass responds. *Am J Publ Health*. 2002;92(11):1708–1709.
10. Optic neuritis and myelitis after booster tetanus toxoid vaccination. <https://pascal-francis.inist.fr/vibad/index.php?action=getRecordDetail&idt=5187254>. Accessed May 22, 2021.
11. *Coronavirus Disease*. Centers for Disease Control and Prevention; 2019. Published April 13, 2021 <https://www.cdc.gov/media/releases/2021/s0413-JJ-vaccine.html>. Accessed May 22, 2021.
12. Shin H-Y, Kim SH, Lee MY, Kim SY, Lee YC. Late emergence of macular sparing in a stroke patient. *Medicine (Baltim)*. 2017;96(29). <https://doi.org/10.1097/MD.00000000000007567>.
13. Nogles TE, Galuska MA. Middle cerebral artery stroke. In: *StatPearls*. StatPearls Publishing; 2021. <http://www.ncbi.nlm.nih.gov/books/NBK556132/>. Accessed May 22, 2021.
14. Kuybu O, Tadi P, Dossani RH. Posterior cerebral artery stroke. In: *StatPearls*. StatPearls Publishing; 2021. <http://www.ncbi.nlm.nih.gov/books/NBK532296/>. Accessed May 22, 2021.
15. Ducros A. Reversible cerebral vasoconstriction syndrome. *Lancet Neurol*. 2012;11(10):906–917. [https://doi.org/10.1016/S1474-4422\(12\)70135-7](https://doi.org/10.1016/S1474-4422(12)70135-7).
16. Allroggen H. Cerebral venous sinus thrombosis. *Postgrad Med*. 2000;76(891):12–15. <https://doi.org/10.1136/pmj.76.891.12>.
17. Pradhan S, Chung SM. Retinal, ophthalmic, or ocular migraine. *Curr Neurol Neurosci Rep*. 2004;4(5):391–397. <https://doi.org/10.1007/s11910-004-0086-5>.
18. Toosy AT, Mason DF, Miller DH. Optic neuritis. *Lancet Neurol*. 2014;13(1):83–99. [https://doi.org/10.1016/S1474-4422\(13\)70259-X](https://doi.org/10.1016/S1474-4422(13)70259-X).
19. Jampol LM, Sieving PA, Pugh D, Fishman GA, Gilbert H. Multiple evanescent white dot syndrome. :4.
20. Acute idiopathic blind spot enlargement syndrome: a review of 27 new cases. *Arch Ophthalmol*. 2001;119:5.
21. UpToDate. <https://www.uptodate.com/contents/reversible-cerebral-vasoconstriction-syndrome>. Accessed May 22, 2021.
22. Chen C-Y, Chen S-P, Fuh J-L, et al. Vascular wall imaging in reversible cerebral vasoconstriction syndrome – a 3-T contrast-enhanced MRI study. *J Headache Pain*. 2018;19(1). <https://doi.org/10.1186/s10194-018-0906-7>.
23. Infectious optic neuropathies: a clinical update. <https://www.ncbi.nlm.nih.gov/pmc/articles/PMC5398737/>. Accessed May 22, 2021.
24. Ng CC, Jumper JM, Cunningham ET. Multiple evanescent white dot syndrome following influenza immunization - a multimodal imaging study. *Am J Ophthalmol Case Rep*. 2020;19. <https://doi.org/10.1016/j.ajoc.2020.100845>.
25. Quinones X, Ortiz J, Santos C, Oliver AL, Rodríguez J. Acute idiopathic blind spot enlargement syndrome following influenza vaccination. *Am J Ophthalmol Case Rep*. 2020;20:100949. <https://doi.org/10.1016/j.ajoc.2020.100949>.
26. Piri N, Kaplan HJ, Sigford DK, Tezel TH. High-definition optical coherence tomography findings in acute idiopathic blind spot enlargement (AIBSE) syndrome. *Ocul Immunol Inflamm*. 2014;22(6):494–496. <https://doi.org/10.3109/09273948.2013.872802>.