

See discussions, stats, and author profiles for this publication at: <https://www.researchgate.net/publication/278159189>

Recurrent Glioblastoma Multiforme (grade IV – WHO 2007): A case of complete objective response – Concomitant administration of Somatostatin / Octreotide, Retinoids, Vit E, Vit D3,...

Article in *Neuro endocrinology letters* · May 2015

Source: PubMed

CITATIONS

6

READS

196

4 authors, including:



Giuseppe Di Bella

Fondazione Di Bella

40 PUBLICATIONS 267 CITATIONS

[SEE PROFILE](#)



Alessandro Ricchi

University of Bologna

3 PUBLICATIONS 29 CITATIONS

[SEE PROFILE](#)

Some of the authors of this publication are also working on these related projects:



Di Bella Method [View project](#)



Biological cancer therapy -Di Bella Method [View project](#)

Recurrent Glioblastoma Multiforme (grade IV – WHO 2007): a case of complete objective response achieved by means of the concomitant administration of Somatostatin and Octreotide – Retinoids – Vit E – Vit D3 – Vit C – Melatonin – D2 R agonists (Di Bella Method – DBM) associated with Temolozomide

Giuseppe Di BELLA, Jovan LECI, Alessandro RICCHI, Rosilde TOSCANO

Di Bella Foundation, Bologna, Italy

Correspondence to: Dr. Giuseppe Di Bella
Di Bella Foundation
Via Marconi 51, Post code 40122, Bologna, Italy.
TEL: +39 051 239662; +39 051 230369; E-MAIL: posta@giuseppedibella.it

Submitted: 2015-04-15 Accepted: 2015-05-03 Published online: 2015-00-00

Key words: Glioblastoma, Retinoic Acid, Somatostatina, Vitamin D, D2 R agonists, Melatonin, Temozolomide, Vitamin E

Neuroendocrinol Lett 2015;36(2):101-106 PMID: ----- NEL360215AXX ©2015 Neuroendocrinology Letters • www.nel.edu

Abstract

In a 41 year old man, with Glioblastoma Multiforme (Grade IV – WHO 2007) and loco-regional recurrence, treated conventionally with surgery, radio-therapy and Temolozomide, a complete objective response was subsequently achieved by means of the well-tolerated concomitant administration of Somatostatin + slow-release Octreotide, Melatonin, Retinoids solubilized in Vitamin E, Vit D3, Vit C, D2 R agonists, and Temolozomide. In addition to the positive and previously unreported therapeutic finding, this result allowed the patient to avoid further surgical trauma and the correlated risks, achieving an excellent quality of life and working capacity.

INTRODUCTION

Among glial tumours, Glioblastoma Multiforme (GBM) is the most common and malignant, and remains a unsolved clinical problem. Despite surgery, which is the treatment of choice for GBM, together with chemo and radiotherapy, post-surgical recurrence and progression are the norm. Survival with surgery, radiotherapy and chemotherapy (Filippini *et al.* 2008) is between 12 and 14 months (57% at 1 year, 16% at 2 years and 7% at 3 years). The rare cases reported in the literature with more than 3 years survival are defined as “long-term survival”. Surgical reduction of the

tumoral mass allows more effective management with radio/chemotherapy. Removal of more than 98% of the tumour volume (“total” resection) increases survival compared to subtotal or partial resection. Subtotal “extended” resection does not appear to provide any advantage in terms of survival compared to biopsy or partial resection (Laws *et al.* 2003) Tyrosine kinase inhibitors (Cenciarelli *et al.* 2014), VEGF inhibitors (Batchelor *et al.* 2014), TT1 inhibitors, PDGF inhibitors, and EGF inhibitors do not appear to have provided significant results, despite their sometimes severe toxicity. Similarly, (Crough *et al.* 2012) immunotherapy, (Mizumoto *et al.* 2013) proton beam

radiotherapy or hadron therapy (Orecchia *et al.* 2014) have not greatly improved prognosis. Surgery followed by a combination of radiotherapy and temozolomide is usually well tolerated but has little efficacy; in the absence of valid alternatives, it has become the standard treatment of choice for glioblastoma.

Due to the absence in the literature of findings of previous complete objective responses of glioblastoma to the usual treatments, we believe it is useful to report our case, which shows that it is possible to increase the efficacy and decrease the toxicity of the current oncotherapy for glioblastoma by combining it with the DBM biological therapy. This case confirms the myeloprotective (Di Bella & Gualano 2006), radioprotective (Lissoni *et al.* 1998) and antitoxic effect (Shokrzadeh *et al.* 2014) of melatonin and a solution of retinoids in vitamin E, and Vit D₃. These molecules allowed the continuous administration of Temozolamide beyond the usual dosage limits. The differentiating, immunomodulating and cytostatic properties of these molecules contributed to this result, together with the antiproliferative effect of somatostatin, octreotide, and prolactin inhibitors.

CASE PRESENTATION

In early October 2012, the patient (a 41-year-old man) presented with increasingly severe headache, unresponsive to therapy and with disabling characteristics.

Instrumental tests revealed a “right greyish, bilobate parieto-occipital neoplasm. Inhomogeneous. Bleeding profusely. Non-encapsulated, with soft consistency and infiltrative appearance. The lesion contains cystic areas and haemorrhagic-necrotic areas.” SPECTROSCOPY: “NAA decrease in cholin and lactate peak, indicating a highly aggressive glial tumour.”

Image 1 = MRI 13.10.2012 (before surgery resection)

16-10-2012 – Surgery with subtotal “extended” resection – Histological and immunohistochemical diagnosis:

- Glioblastoma (grade IV WHO 2007)
- EGFR: intense and widespread membrane and cytoplasm positivity in 90% of the neoplastic tissue
- Ki67: proliferating cell fraction: 30%
- PTEN: positive

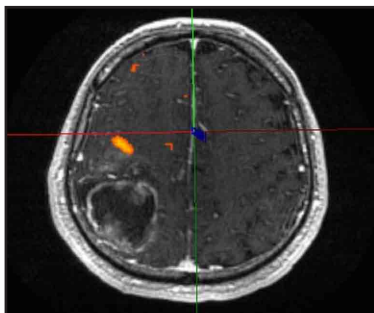


Image 1

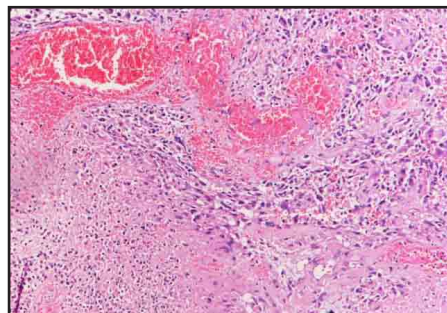


Image 2

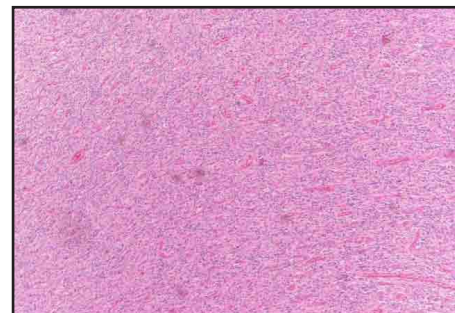


Image 3

Images 2–3 (pathological tissue)

26-10-2012 – MRI “...contrast medium revealed a few small rounded images in front of the surgical cavity, with hyperintense annulets, indicating residual and/or recurrent tumour cells...”

02-11-2012 – CT scan with contrast medium “... the presence of multilobate annulet formations persists after contrast medium injection, indicating residual and/or recurrent tumour cells ...”

Before proceeding to the next stage of therapy (Temodal + Radiotherapy) the patient was prescribed continuous administration of the following:

Somatostatin – Octreotide – Melatonin – Retinoids – Vit. D₃ – Tetracosactide – Cabergoline – Bromocriptine
03-12-2012/18-01-2013: RADIOTHERAPY + Temodal (140mg/day for 5 days/week)

After 4 weeks suspension, Temodal was administered for 5 consecutive days (300 mg/day) every 4 weeks.

5-06-2013 – MRI “...although less evident, the irregular impregnation of the surgical area by contrast medium persists, with the presence of a nodular-like formation of around 20 mm...” “... the other nodule at the rear, measuring around 8 mm, can no longer be seen. The annulet formation deep in the right front area is reduced in size, now measuring around 11 mm (vs 16 mm)...”

Images 4–5 = MRI 05.06.2013 (reduction in size of nodular images)

18-09-2013 – MRI and SPECTROSCOPY “...compared to the previous MRI, less impregnation of the surgical area by contrast medium, the previously indicated nodular formation is no longer evident, the annulet formation in the right front area is considerably smaller and now appears linear and around 4 mm. SPECTROSCOPY with multivoxel technique, with ROI positioned in the lesional area and in healthy tissue, did not show significant variations of the known metabolites in the lesional area with respect to the healthy tissue...”

06-02-2014 – MRI and SPECTROSCOPY “...further reduction of the impregnation of the walls of the operative site. No nodular images in this site. The linear impregnation in the right front area is no longer evident. The edematous halo is also reduced with slight compression on the right ventricular trigone, which

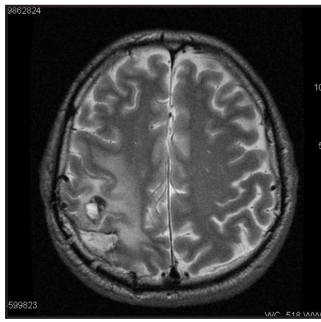


Image 4

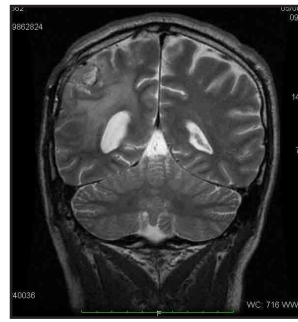


Image 5

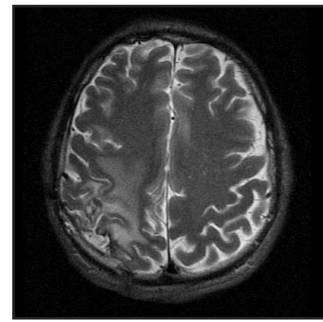


Image 6

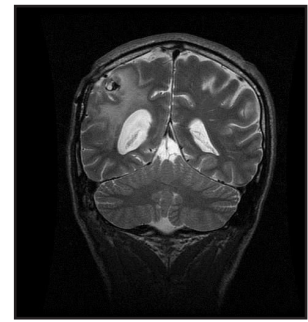


Image 7

appears more expanded compared to the previous finding. SPECTROSCOPY with multivoxel technique, with ROI positioned in the lesional area and in healthy tissue, did not show significant variations of the known metabolites in the lesional area with respect to the healthy tissue...”

Images 6–7 = MRI 03.02.2014 (absence of nodular images)

TREATMENT

- Somatostatin (14 peptide amino acids) 3 mg – subcutaneous (daily, at night – 12 hours infusion)
- Octreotide LAR 20 mg (8 peptide amino acids) 20 mg intramuscular (every 3 weeks)
- Melatonin conjugated (12% – Adenosine 51% – Glycine 37%) 100 mg (daily – oral)
- Retinoid solution 8 ml – oral – 3 times a day
- (ATRA 0.5 g – palmitate axerophthole 0.5 g – BetaCarotene 2 g. Alpha Tocopheryl Acet. 1000 g.
- Vit. D₃ – 1,25 – diOH-Tachysterol 100 mg/day – oral – administered in 3 times
- Tetracosactide Acetate 0.25 mg intramuscular (twice a week)
- Cabergoline 0.5 mg – ½ tab – oral (twice a week)
- Bromocriptine 2.5 mg – ½ tab – oral (twice a day)
- Temodal (300 mg/day) every 4 weeks (now reduced to 200 mg)

RESULTS

The patient, until the last had contact with the Foundation, in the month of September 2014, presents no substantial modifications with respect to the clinical situation described above.

In view of the result achieved, the administration of Temodal has been reduced to 200 mg/day × 5 days every 4 weeks, while the other prescribed substances remain unchanged.

DISCUSSION

Immunohistochemical and western blotting techniques confirmed the existence of the expression of GHR in the CNS, supporting the role of GH in the physiology of the CNS and to an even greater extent in tumours (Castro *et al.* 2000).

In tumours of the CNS a markedly higher expression of GH and GHR in tumours than in healthy tissue is confirmed, with a directly proportional dose-dependent ratio between GH, GHR and tumour aggressiveness (Lincoln *et al.* 1998) In glioblastoma cells, studies have confirmed the anticancer efficacy of somatostatin analogues and the correlation between their anticancer activity and the ability to inhibit the release of GH, antagonizing GHRH.

The hypothalamic GHRH stimulates the synthesis and release of GH by the pituitary gland and its mRNA has been detected at markedly higher concentrations in brain, breast, ovary, prostate and lung tumour tissues than in healthy tissues. Various studies have demonstrated that the somatostatin analogues, GHRH antagonists, also cross the blood-brain barrier without difficulty (Jaeger *et al.* 2005) and, inhibiting GH, have antiproliferative effects in many brain tumour models, including glioblastomas (Kovács *et al.* 2010)

The IGFR respond mitogenically to IGF, and the suppressive effect of SST and its analogues on serum levels of IGF1 is both direct, through the inhibition of the IGF gene, and indirect, through suppression of GH and thus of its hepatic induction of IGF1.

The anti-proliferative effect of the somatostatin analogues in brain tumours as in other neoplasms therefore also takes place through mechanisms that involve the suppression of the IGF system (Kiaris *et al.* 2005) The regression of a primary gliosarcoma, a rare tumour with a short and unfavourable prognosis (considered as a variation of a glioblastoma multiforme like a grade IV tumour) and the long-term survival achieved with somatostatin confirms the efficacy and the indication of SST in this disease (Trignani *et al.* 2013). Another antiblastic mechanism of the somatostatin analogues in glioblastomas, but very probably also in other tumours,

consists of a reduction of telomerase activity, closely connected with tumour growth (Kiaris & Schally 1999). The decrease in GH is also a known consequence of the irradiation of the CNS, and is a collateral antitumoral mechanism of brain radiotherapy, especially if centered on the interbrain area. The relationship between the radiotherapy dose to the hypothalamus and the clinically significant reduction of GH is still not sufficiently known (Merchant *et al.* 2002). Various clinical studies have shown that the radio-marked analogue of somatostatin (DOTATOC), locally injected through a catheter in glioblastomas, has achieved complete or partial remission (Heute *et al.* 2010). These findings further confirm the indication and rationale of SST and its radio-marked analogue in the treatment of glioblastomas.

As in various types of cancer, brain tumours show increased serum levels of PRL and its receptors, confirming its important mitogenic role in the growth of these tumours (Ciccarelli *et al.* 2001).

Immunohistochemical techniques have shown an increased presence of prolactin in brain tumours, while its expression is absent at quantitative-real-time PCR (Mendes *et al.* 2013).

This shows that the presence of PRL in primary tumours of the CNS is initially only hypophyseal; in addition to the mitogenic effect of this molecule, this confirms the still underestimated ability of the neoplastic cell to select and maintain increasing proliferative activity during its mutation, through the autocrine production of hormones and growth factors including prolactin and its receptor with activation of the relative proliferative signalling pathways.

The study by Oliveira-Ferrer *et al.* (2013) provides confirmation; in fact, integrin ligands with apoptotic and anti-angiogenic activity, such as endostatin and tumstatin, exert their anti-proliferative activity through angiogenesis inhibition, but their effect is not permanent due to the aforementioned mutagenic ability of the tumour cells which, in response to any anticancer treatment (especially if mono-target), defend themselves by releasing hormones and growth factors in an autocrine manner.

In the battery of identified genes, an over-expression of PRLR and its ligand has been observed. The genic activation of prolactin receptors and its ligand thus represents a mechanism of evasion and resistance to the treatment with Endostatin-Tumstatin. The authors emphasise the mitogenic role in this over-regulation of prolactin on various tumour forms.

These observations confirm the rationale of the anti-proliferative synergic inhibition by means of PRL and GH inhibitors and of the differentiating inhibition with Retinoids, Vit. E, D₃, and MLT as part of an interactive centripetal multi-factor treatment of tumour cells. In glioblastomas, as in other tumours, stem tumour cells are sensitive to the differentiating effects of retinoids (Karsy *et al.* 2010), which also have cytostatic effects

(Campos *et al.* 2010), reinforcing the anticancer action of Temozolomide (Jaeckle *et al.* 2003) and other chemotherapy drugs (Das *et al.* 2008).

Both physiological and tumour cell proliferation depend to a great extent on prolactin, GH, the greatest growth (De Souza *et al.* 1974; Ben-Jonathan *et al.* 2002; Lincoln *et al.* 1998; Friend 2000) and on GH-dependent mitogenic molecules positively regulated by GH such as EGF, FGF, HGF, IGF1-2, NGF, PDGF, TGF, VEGF (Hagemester & Sheridan 2008; Taslipinar *et al.* 2009) as well as growth factors produced by the digestive system, such as VIP, CCK, G (Kath & Höffken 2000). The powerful mitogenic role is confirmed by studies showing markedly higher concentrations of GHR in tumour cells compared with peritumoural and physiological tissues (Zeitler & Siriwardana 2000; Gruszka *et al.* 2001). The temporal mechanism of this etiopathogenetic process is currently being investigated: among the most likely hypotheses, in addition to the pituitary secretion of GH and PRL, probable mechanisms of autocrine and/or paracrine signalling mechanisms have been suggested, based on the detection of local production.

Angiogenesis is an obligatory step in tumour expansion, involving angiogenic inductors such as monocyte chemotaxis, endothelial Nitric Oxide Synthase, interleukin 8 Prostaglandin 2, Vaso intestinal peptide, and angiogenic growth factors such as VEGF, TGF, IGF1, FGF, HGF, and PDGF. All these molecules are negatively regulated by somatostatin and its analogues (Albini *et al.* 1999; Cascinu *et al.* 2001) and, albeit to a lesser extent, by other components of the DBM such as MLT (Lissoni *et al.* 2001) Retinoids (Kini *et al.* 2001), vitamin D3 (Kisker *et al.* 2003), Vitamin E (Neuzil *et al.* 2002), Vitamin C (Ashino *et al.* 2003), prolactin inhibitors (Turner *et al.* 2000) and by components of the extracellular matrix (Liu *et al.* 2005). While angiogenesis is an obligatory step in tumour expansion, and angiogenesis is inhibited by somatostatin, the indication for somatostatin, with or without SSTR, in all tumours is further clarified and documented.

Local situations of anoxia and acidosis also favour angiogenesis, and are corrected to a great extent by the improvement in blood-tissue exchanges induced by the components of the DBM.

EGF, which has an important mitogenic role in many cases of glioblastoma is inhibited by SST through many mechanisms: block of the dose-dependent signalling (inhibition of tyrosine phosphorylation) of EGFR (Mishima *et al.* 1999), reduction of the expression of EGFR and its ligand (EGF) in tumour cells, reduction of the plasma concentration of EGF (Castro *et al.* 2000). This effect is further reinforced by the concomitant administration of MLT and Vitamin D3, whose negative regulation of epidermal growth factors has been documented (Di Bella 2010).

The objective response of this case, in the absence of toxicity, encouraged us to propose its publication. To overcome the toxicity and limitations of the current

oncological treatments, we believe it is worth drawing attention to the interactive and synergic biochemical and molecular mechanisms of the components of the DBM and to the already published positive clinical results achieved in lung, breast, and prostate tumours and in lymphoproliferative diseases.

REFERENCES

- 1 Albini A, Florio T, Giunciuglio D, Masiello L, Carlone S, Corsaro A *et al.* (1999). Somatostatin controls Kaposi's sarcoma tumor growth through inhibition of angiogenesis. *FASEB J.* **13**(6): 647–655.
- 2 Ashino H, Shimamura M, Nakajima H, Dombou M, Kawanaka S, Oikawa T, Iwaguchi T, Kawashima S (2003). Novel function of ascorbic acid as an angiostatic factor. *Angiogenesis.* **6**(4): 259–269.
- 3 Batchelor TT, Reardon DA, de Groot JF, Wick W, Weller M (2014). Antiangiogenic therapy for glioblastoma: current status and future prospects. *Clin Cancer Res.* **20**(22): 5612–5619.
- 4 Ben-Jonathan N, Liby K, McFarland M, Zinger M (2002). Prolactin as an autocrine/paracrine growth factor in human cancer. *Trends Endocrinol Metab.* **13**(6): 245–250.
- 5 Campos B, Wan F, Farhadi M, Ernst A, Zeppernick F, Tagscherer KE (2010). Differentiation therapy exerts antitumor effects on stem-like glioma cells. *Clin Cancer Res.* **16**(10): 2715–2728.
- 6 Cascinu S, Del Ferro E, Ligi M, Staccioli MP, Giordani P, Catalano V *et al.* (2001). Inhibition of vascular endothelial growth factor by octreotide in colorectal cancer patients. *Cancer Invest.* **19**(1): 8–12.
- 7 Castro JR, Costoya JA, Gallego R, Prieto A, Arce VM, Señaris R (2000). Expression of growth hormone receptor in the human brain. *Neurosci Lett.* **281**(2–3): 147–150.
- 8 Cenciarelli C, Marei HE, Zonfrillo M, Pierimarchi P, Paldino E, Casalbone P, Felsani A, Vescovi AL, Maira G, Mangiola A (2014). PDGF receptor alpha inhibition induces apoptosis in glioblastoma cancer stem cells refractory to anti-Notch and anti-EGFR treatment. *Mol Cancer.* **13**(1): 247.
- 9 Ciccarelli E, Razzore P, Gaia D, Todaro C, Longo A, Forni M, Ghè C, Camanni F *et al.* (2001). Hyperprolactinaemia and prolactin binding in benign intracranial tumours. *J Neurosurg Sci.* **45**(2): 70–74.
- 10 Crough T, Beagley L, Smith C, Jones L, Walker DG, Khanna R (2012). Ex vivo functional analysis, expansion and adoptive transfer of cytomegalovirus-specific T-cells in patients with glioblastoma multiforme. *Immunol Cell Biol.* **90**(9): 872–880.
- 11 Das A, Banik NL, Ray SK (2008). Retinoids induced astrocytic differentiation with down regulation of telomerase activity and enhanced sensitivity to taxol for apoptosis in human glioblastoma T98G and U87MG cells. *J Neurooncol.* **87**(1): 9–22. Epub 2007 Nov 7.
- 12 De Souza I, Morgan L, Lewis UL, Raggatt PR, Salih H, Hobbs JR (1974). Growth-hormone dependence among human breast cancers. *Lancet.* **2**(7874): 182–184.
- 13 Di Bella L, Gualano L (2006). Key aspects of melatonin physiology: thirty years of research. *Neuro Endocrinol Lett.* **27**(4): 425–432.
- 14 Di Bella G (2010). The Di Bella Method (DBM). *Neuro Endocrinol Lett.* **31** (Suppl 1): 1–42.
- 15 Filippini G, Falcone C, Boiardi A, Broggi G, Bruzzone MG, Caldiroli D, Farina R, Farinotti M, *et al.* (2008). Prognostic factors for survival in 676 consecutive patients with newly diagnosed primary glioblastoma. *Neuro Oncol.* **10**(1): 79–87.
- 16 Friend KE (2000). Targeting the growth hormone axis as a therapeutic strategy in oncology. *Growth Horm IGF Res.* **10** (Suppl A): S45–6. Review.
- 17 Gruszka A, Pawlikowski M, Kunert-Radek J (2001). Anti-tumoral action of octreotide and bromocriptine on the experimental rat prolactinoma: anti-proliferative and pro-apoptotic effects. *Neuro Endocrinol Lett.* **22**(5): 343–348.
- 18 Hagemester AL, Sheridan MA (2008). Somatostatin inhibits hepatic growth hormone receptor and insulin-like growth factor I mRNA expression by activating the ERK and PI3K signaling pathways. *Am J Physiol Regul Integr Comp Physiol.* **295**(2): R490–497.
- 19 Heute D, Kostron H, von Guggenberg E, Ingorokva S, Gabriel M, Dobrozemsky G, Stockhammer G, Virgolini IJ (2010). Response of recurrent high-grade glioma to treatment with (90)Y-DOTATOC. *J Nucl Med.* **51**(3): 397–400.
- 20 Jaeckle KA, Hess KR, Yung WK, Greenberg H, Fine H, Schiff D *et al.* (2003). Phase II evaluation of temozolomide and 13-cis-retinoic acid for the treatment of recurrent and progressive malignant glioma: a North American Brain Tumor Consortium study. *J Clin Oncol.* **21**(12): 2305–2311.
- 21 Jaeger LB, Banks WA, Varga JL, Schally AV (2005). Antagonists of growth hormone-releasing hormone cross the blood-brain barrier: a potential applicability to treatment of brain tumors. *Proc Natl Acad Sci U S A.* **102**(35): 12495–12500.
- 22 Karsy M, Albert L, Tobias ME, Murali R, Jhanwar-Uniyal M (2010). All-trans retinoic acid modulates cancer stem cells of glioblastoma multiforme in an MAPK-dependent manner. *Anticancer Res.* **30**(12): 4915–4920.
- 23 Kath R, Höffken K (2000). The significance of somatostatin analogues in the antiproliferative treatment of carcinomas. *Recent Results Cancer Res.* **153**: 23–43.
- 24 Kiaris H, Schally AV, Kalofoutis A (2005). Extrapituitary effects of the growth hormone-releasing hormone. *Vitam Horm.* **70**: 1–24.
- 25 Kiaris H, Schally AV (1999). Decrease in telomerase activity in U-87MG human glioblastomas after treatment with an antagonist of growth hormone-releasing hormone. *Proc Natl Acad Sci U S A.* **96**(1): 226–231.
- 26 Kini AR, Peterson LA, Tallman MS, Lingen MW (2001). Angiogenesis in acute promyelocytic leukemia: induction by vascular endothelial growth factor and inhibition by all-trans retinoic acid. *Blood.* **97**(12): 3919–3924.
- 27 Kisker O, Onizuka S, Becker CM, Fannon M, Flynn E, D'Amato R *et al.* (2003). Vitamin D binding protein-macrophage activating factor (DBP-maf) inhibits angiogenesis and tumor growth in mice. *Neoplasia.* **5**(1): 32–40.
- 28 Kovács M, Schally AV, Hohla F, Rick FG, Pozsgai E, Szalontay L, Varga JL, Zarándi M (2010). A correlation of endocrine and anticancer effects of some antagonists of GHRH. *Peptides.* **31**(10): 1839–1846.
- 29 Laws ER, Parney IF, Huang W, Anderson F, Morris AM, Asher A *et al.* (2003). Survival following surgery and prognostic factors for recently diagnosed malignant glioma: data from the Glioma Outcomes Project. *J Neurosurg.* **99**(3): 467–473.
- 30 Lincoln DT, Sinowatz F, Temmim-Baker L, Baker HI, Kölle S, Waters MJ (1998). Growth hormone receptor expression in the nucleus and cytoplasm of normal and neoplastic cells. *Histochem Cell Biol.* **109**(2): 141–159.
- 31 Lissoni P, Giani L, Zerbini S, Trabattini P, Rovelli F (1998). Biotherapy with the pineal immunomodulating hormone melatonin versus melatonin plus aloe vera in untreatable advanced solid neoplasms. *Nat Immun.* **16**(1): 27–33.
- 32 Lissoni P, Rovelli F, Malugani F, Bucovec R, Conti A, Maestroni GJ (2001). Anti-angiogenic activity of melatonin in advanced cancer patients. *Neuro Endocrinol Lett.* **22**(1): 45–47.
- 33 Liu Y, Yang H, Otaka K, Takatsuki H, Sakanishi A (2005). Effects of vascular endothelial growth factor (VEGF) and chondroitin sulfate A on human monocytic THP-1 cell migration. *Colloids Surf B Biointerfaces.* **43**(3–4): 216–220.
- 34 Mendes GA, Pereira-Lima JF, Kohek MB, Trott G, Di Domenico M, Ferreira NP, Oliveira Mda C (2013). Prolactin gene expression in primary central nervous system tumors. *J Negat Results Biomed.* **12**(1): 4.
- 35 Merchant TE, Golubeva O, Pritchard DL, Gaber MW, Xiong X, Danish RK, Lustig RH (2002). Radiation dose-volume effects on growth hormone secretion. *Int J Radiat Oncol Biol Phys.* **52**(5): 1264–1270.

- 36 Mishima M, Yano T, Jimbo H, Yano N, Morita Y, Yoshikawa H, Schally AV, Taketani Y (1999). Inhibition of human endometrial cancer cell growth in vitro and in vivo by somatostatin analog RC-160. *Am J Obstet Gynecol.* **181**(3): 583–590.
- 37 Mizumoto M, Okumura T, Ishikawa E, Yamamoto T, Takano S, Matsumura A *et al.* (2013). Reirradiation for recurrent malignant brain tumor with radiotherapy or proton beam therapy. Technical considerations based on experience at a single institution. *Strahlenther Onkol.* **189**(8): 656–663.
- 38 Neuzil J, Kågedal K, Andera L, Weber C, Brunk UT (2002). Vitamin E analogs: a new class of multiple action agents with anti-neoplastic and anti-atherogenic activity. *Apoptosis.* **7**(2): 179–187.
- 39 Oliveira-Ferrer L, Wellbrock J, Bartsch U, Penas EM, Hauschild J, Klokow M *et al.* (2013). Combination therapy targeting integrins reduces glioblastoma tumor growth through antiangiogenic and direct antitumor activity and leads to activation of the proliferative prolactin pathway. *Mol Cancer.* **12**(1): 144.
- 40 Orecchia R, Vitolo V, Fiore MR, Fossati P, Iannalfi A, Vischioni B *et al.* (2014). Proton beam radiotherapy: report of the first ten patients treated at the “Centro Nazionale di Adroterapia Oncologica (CNAO)” for skull base and spine tumours. *Radiol Med.* **119**(4): 277–282.
- 41 Shokrzadeh M, Ahmadi A, Naghshvar F, Chabra A, Jafarnejhad M (2014). Prophylactic efficacy of melatonin on cyclophosphamide-induced liver toxicity in mice. *Biomed Res Int.* **2014**: 470425.
- 42 Trignani M, Taraborrelli M, Ausili Cèfaro G (2013). The case of a patient affected by primary gliosarcoma and neuroendocrine pancreatic cancer with prolonged survival. *Tumori.* **99**(3): e117–119.
- 43 Taslipinar A, Bolu E, Kebapçilar L, Sahin M, Uckaya G, Kutlu M (2009). Insulin-like growth factor-1 is essential to the increased mortality caused by excess growth hormone: a case of thyroid cancer and non-Hodgkin’s lymphoma in a patient with pituitary acromegaly. *Med Oncol.* **26**(1): 62–66.
- 44 Turner HE, Nagy Z, Gatter KC, Esiri MM, Harris AL, Wass JA (2000). Angiogenesis in pituitary adenomas – relationship to endocrine function, treatment and outcome. *J Endocrinol.* **165**(2): 475–481.
- 45 Zeitler P, Siriwardana G (2000). Stimulation of mitogen-activated protein kinase pathway in rat somatotrophs by growth hormone-releasing hormone. *Endocrine.* **12**(3): 257–264.