

Complete objective response to biological therapy of plurifocal breast carcinoma

Giuseppe DI BELLA

Di Bella Foundation, Bologna, Italy.

Correspondence to: Giuseppe Di Bella, MD. PhD.
Via Marconi n 51, Bologna 40122 - Italy
TEL: +39-051-239662; +39-051-230369; FAX: +39-051-2961283
E-MAIL: posta@giuseppedibella.it

Submitted: 2008-05-30 *Accepted:* 2008-09-01 *Published online:* 2008-12-29

Key words: **breast carcinoma; remission induction; biological therapy; somatostatine; melatonin**

Neuroendocrinol Lett 2008; **29**(6):101-000 PMID: 19112416 NEL290608C03 © 2008 Neuroendocrinology Letters • www.nel.edu

Abstract

In this case presentation, a woman with breast carcinoma who chose to try Prof. L. DiBella's biological therapy (MDB), was found, after seven months, to have a 50% reduction in objective measures of her carcinoma and was totally cured after 14 months. The patient's recovery extended to bilateral axillary adenopathies, and took place without the toxicity normally associated with cancer treatment. MDB entails the use of anti-proliferative molecules such as somatostatine, prolactin, and estrogen inhibitors, along with differentiating and apoptotic molecules such as melatonin, retinoids, vitamins C, D3, and E, calcium, and amino-sugars, combined with minimal doses of chemotherapy. The hemato-chemical exams showed no damage, with a progressive reduction of prolactin, estradiol, IGF1, and maintenance of low levels of GH. The achievement of objective results, without toxicity, in this case, proves the effectiveness of this therapy and confirms the positive results already published on the use of MDB for Low-Grade NHL, and pulmonary carcinomas in the 3rd and 4th stages. MDB, without the need for either hospitalization or day hospitalization, without toxicity, and without even minimally reducing the patient's daily work routine, allowed the patient to avoid surgical trauma and the significant collateral effects of chemo- and radiotherapy. Timely use of MDB as the first line therapy, in a patient which had not been debilitated by the mutagenic, toxic, and immuno-depressive effects of chemo- and radiotherapy, contributed greatly to the final outcome. We feel it is useful to highlight this case in an effort to stimulate interest and further study into the oncological potential of MDB biological and receptor therapy.

INTRODUCTION

The following is a case of complete remission of a multifocal mammary carcinoma in a 51 year old woman. The carcinoma had 3 distinct locations in the left breast, had infiltrated both ducts and lobes, and exhibited bilateral microfibrocystic alterations with evident bilateral reactive axillary lymphadenopathy. Additionally, 2 small cerebral lesions of, suspected, but unconfirmed metastatic origin were revealed by contrast MRI.

The following are the essentials of the MDB (Di Bella Method) biological therapy carried out, and the histological and hemato-chemical tests, in addition to the diagnostic tests, performed before and after MDB treatment. Additionally we provide an extremely synthesized description of the MDB rationale, with documentation of the scientific basis for the treatment.

Abbreviations

ATRA	– All Trans Retinoic Acid
CCK	– Cholecystokinin
MDB	– Di Bella's Method
EGF	– Epidermal Growth Factor
EGFR	– Epidermal Growth Factor Receptor
FGF	– Fibroblastic Growth Factor
GH	– Growth Hormone
GHR	– Growth Hormone Receptor
HGF	– Hepatocyte Growth Factor,
IGF1-2	– Insulin-like Growth Factor 1-2
IGFR	– Insulin-like Growth Factor Receptor
MRI	– Magnetic Resonance Imaging
MLT	– Melatonin
NGF	– Nerve Growth Factor
NHL	– Non-Hodgkin's Lymphoma
PG	– Pentagastrin
PDGF	– Platelet-Derived Growth Factor
PET	– Positron Emission Tomography
SST	– Somatostatin
SSTR	– Somatostatin Receptor
TGF	– Transforming Growth Factor
VEGF	– Vascular Endothelial Growth Factor
VIP	– Vasoactive Intestinal Peptide

CLINICAL CASE

The patient was 51 years old female, weighing 62 kg, and having 2 children. She was 11 years old at menarche, had a history of regular menstruation, and had taken estrogen-progestogen birth control pill since age 45. On examination the patient's nipples appeared normal; ducts dilated, and absent secretions. The first symptoms appeared in January 2006.

Diagnosis and therapy, which was formulated by the "Centro Diagnostico Terapeutico per la Mammella" (Diagnostic Therapeutic Center for Breasts) - Oncology Institute of the University of Ferrara – Italy, reported the following: "Micro-cystic macro-cystic mastopathy with some macro-cystic areas and ductal ectasy, discrete adipose component, mainly pre-glandular. Axillary lymphadenopathy more pronounced on the left side with no evident architectural disorganization."

- Location: upper-internal left quadrant
- Distance from cutis: 3.6 mm,
- Distance from nipple: 22 mm
- Edges indistinct
- Low echogenicity
- Reduced subcutaneous adipose stratum
- Age tumor appeared: 51 years
- Distance from fascia: 1.0 mm
- Dimensions (the largest of 3 neoplasms) 13.8 × 15.7 × 11 mm
- Margins of neoplasm finely irregular
- Cutaneous echogenicity normal
- Reduced retro adipose stratum

Proliferative processes:

1. left breast in 9 a.m. ray 10 × 11 × 9.7 mm to 3.6 mm from cutis and to 2.6 mm from fascia, to 30 mm from nipple

2. from 11 a.m. ray to 11.30 of 13.6 × 11 × 15.7 mm of the upper-internal quadrant of left breast
3. of upper left haemiteic line of 5.5 × 4.4 × 4.4 mm

Core Biopsies of lesions 1) and 2) were performed and sent for examination to the University of Ferrara's Department of Pathology and Oncology, which formulated the following histopathological diagnosis:

1. "Infiltrating ductal carcinoma, coexisting pagetoid propagation of globular in situ carcinoma of ducts."
2. "Infiltrating ductal and lobular carcinoma; coexisting lobular in situ carcinoma."

Six frustules of the core biopsy were sent for consultation to the Institute of Pathological Anatomy at the University of Bologna – Bellaria Hospital, which reported the following: "2nd degree invasive ductal carcinoma, associated with in situ carcinoma, probably globular (B5)."

Immunohistochemical diagnosis:

Estrogen Receptor:	99.5% positive
Progesterone Receptor:	80.4% positive
Expression of EGF Receptor:	0.00%

Figures 1–4.

Additional diagnostic tests:

February 9, 2006 – X-ray (mammogram).
Figures 5, 6.

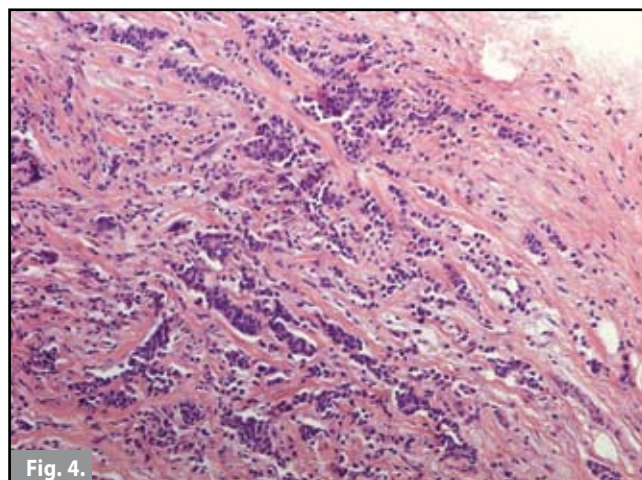
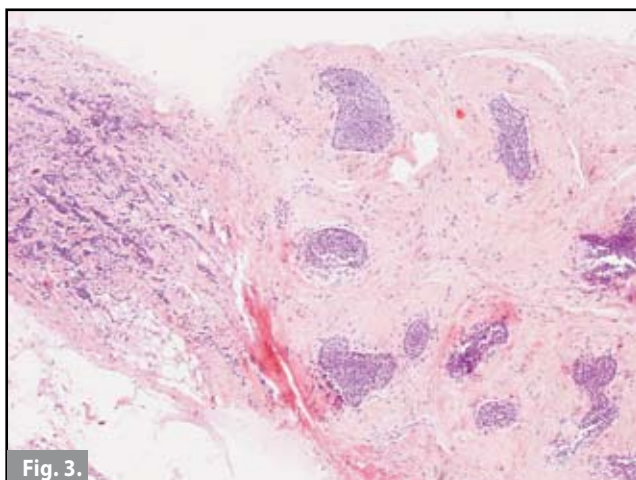
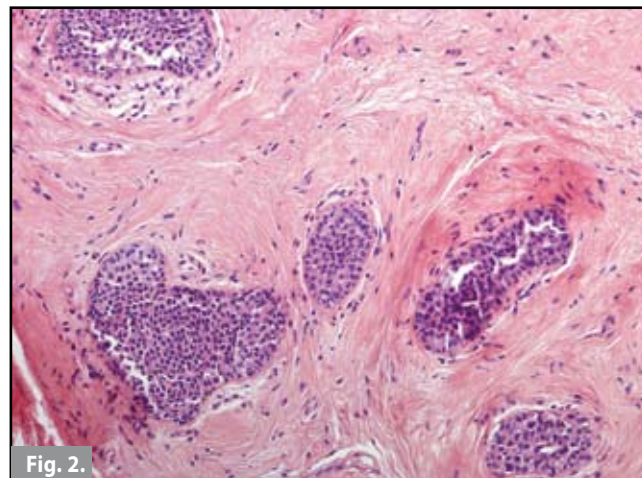
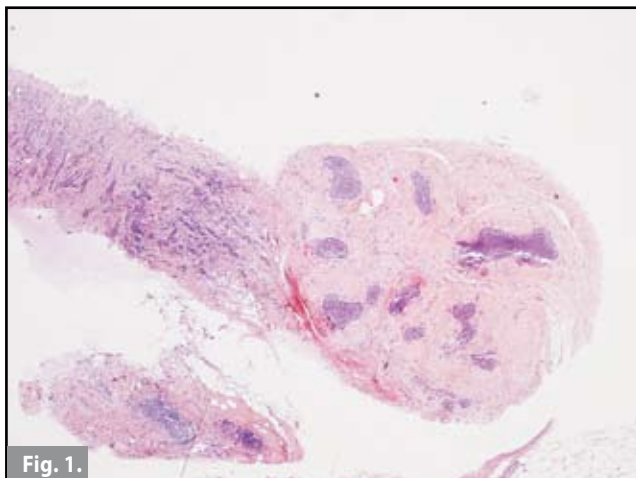
February 15, 2006 - Breast ultra-sound. Figures 7–9. Diagnostic conclusions from the University of Ferrara's: "Left mammary neoplasia (infiltrating globular and ductal carcinoma), cerebral alteration of unidentified histological nature." The proposed therapy consisted of: total mastectomy with removal of axillary lymph nodes followed by radio-chemotherapy.

At the end of the clinical report, issued to the patient on March 14, 2006, the following was highlighted: "We strongly suggest that surgery not be postponed."

March 22, 2006 — The patient, refused the suggested treatment plan and began Prof. Luigi DiBella's biological therapy (MDB).

Diagnostic tests carried out during MDB treatment.

October 18, 2006 – Approximately 7 months after initiation of MDB treatment, an ultra-sound showed that the bilateral axillary adenopathy of 2 of the 3 neoplastic lesions had disappeared, and the residual tumor size had been reduced to 9 mm. Report: "Non-homogeneous glandular structures with small scattered cystic areas and ectatic ducts in the areolar areas. In the upper left sector of the left breast, at 11 a.m., a hypoechoic area with irregular edges with a long axis of 9 mm. No other suspicious elements, with the exception of small



Figures 1–4. Histological finds (Feb. 16, 2006).

areas of architectural disorder in the left inferomedial sector; no axillary, supraclavicular or, as far as can be seen, internal mammary adenopathies.”

December 14, 2006 – After an additional 2 months, (nine months total), an ultra-sound documented further reductions in tumor size; “The current examination compared to the previous one of February 2006, shows that the expansive infiltrative formation noted in the left breast at 11:30 a.m. is reduced in size and currently measures 6 mm. No pathological images on the right breast. We advise eco-mammography checks in view of the relative density of the glandular component.”

April 5, 2007 – Ultra-sound: “no structural alterations in the right breast. In the upper internal quadrant of the left breast, near the median sagittal plane, the hypoechogenic area with irregular margins previously examined by needle aspiration, with extenuation of the ultra-sound tractus of $5.8 \times 3.8 \times 5.1$ mm. The most superficial margin of this formation is one centimeter from the cutaneous plane and approximately 3 mm from the muscular fascia. No lymphadenopathy suspected in the axillary and supraclavicular regions.”

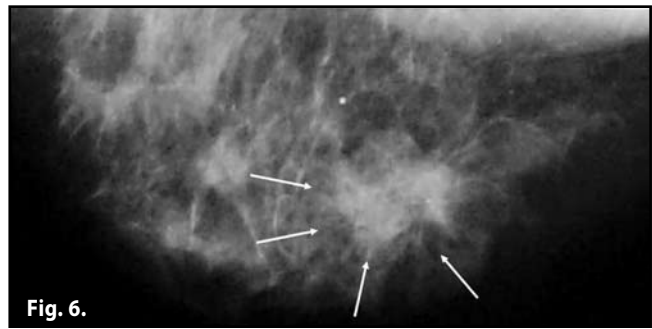
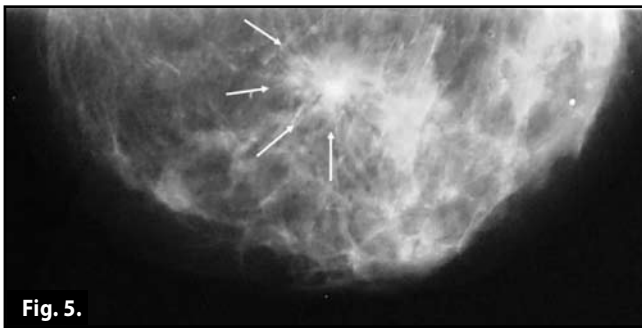
August 28, 2007 – Bilateral MRI with and without contrast: “In the T2 sequence weighed in the context of both glandular bodies, some minute cystic formations can be seen. After administration of the contrast substance, there were no areas with bilaterally suspect enhancement. Specifically there were no expansive formations in correspondence to the hypoechogenic area with posterior acoustic obstruction as previously described in the ultra-sound exam.”

September 18, 2007 – Total corporeal bone and articular scintigraphy: negative. Figure 10.

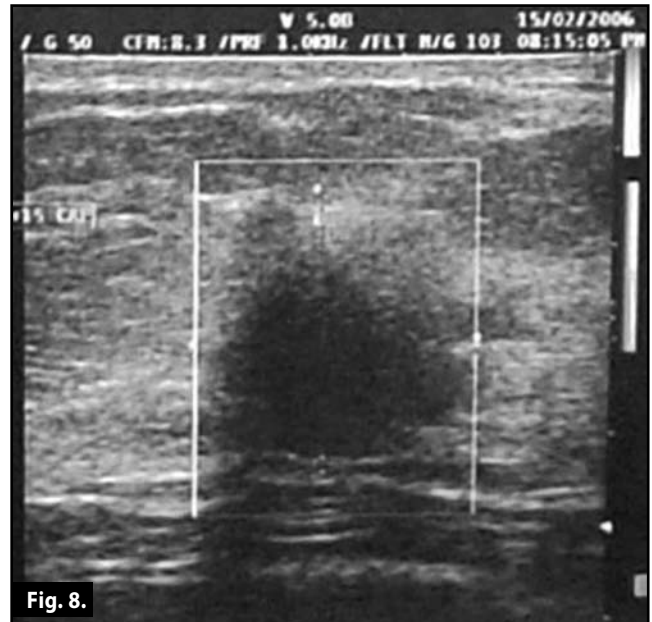
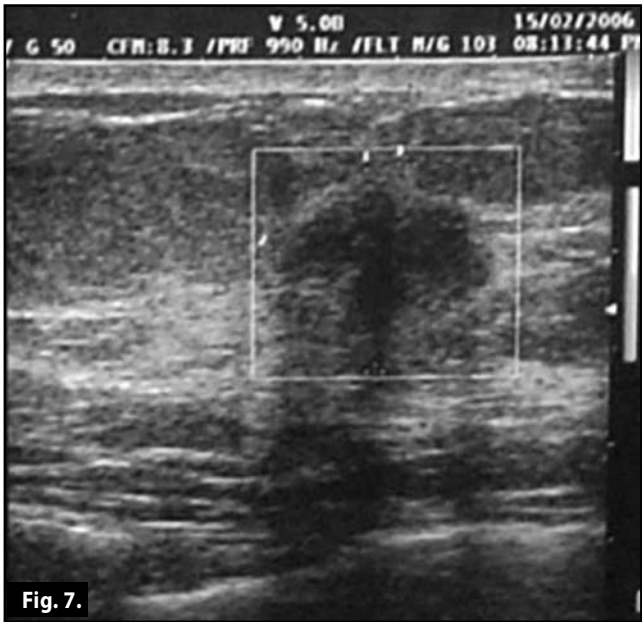
September 20, 2007 – Chest X-ray: negative

September 20, 2007 – Complete abdominal ultra-sound: negative

October 12, 2007 – PET confirms the absence of neoplastic lesions: “The PET with 18 F-FDG did not show the presence of areas of pathological accumulation of the radiopharmaceutical ascribable to lesions with high metabolic activity.” Figure 11.



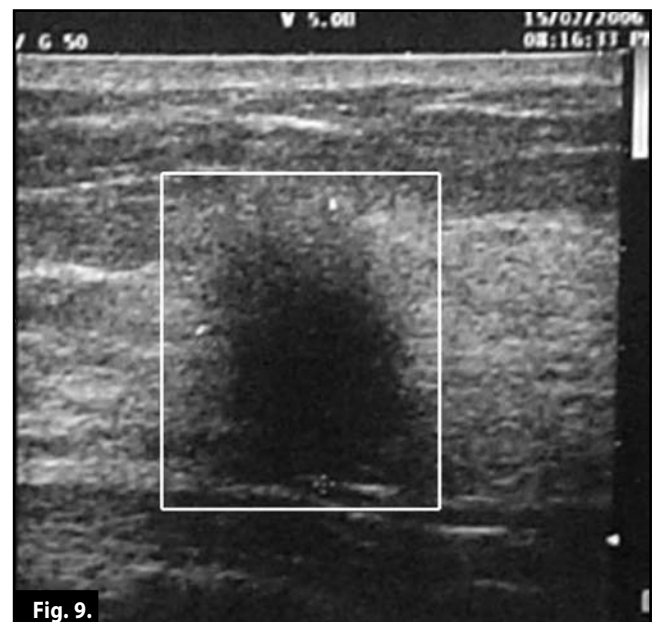
Figures 5-6: Stellar formation with indented, ill-defined contours, ascribable to a tumour (Feb. 09, 2006)

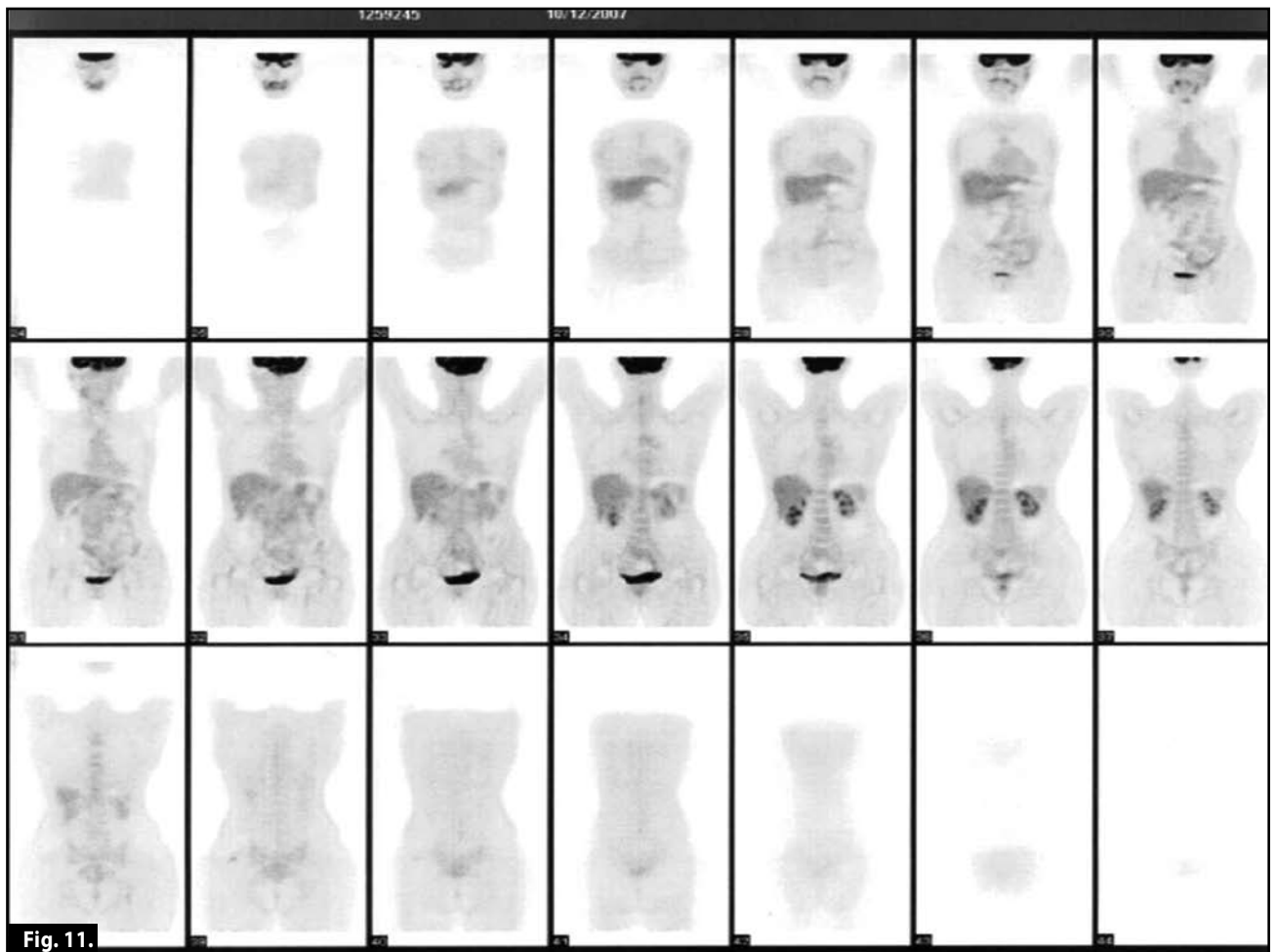
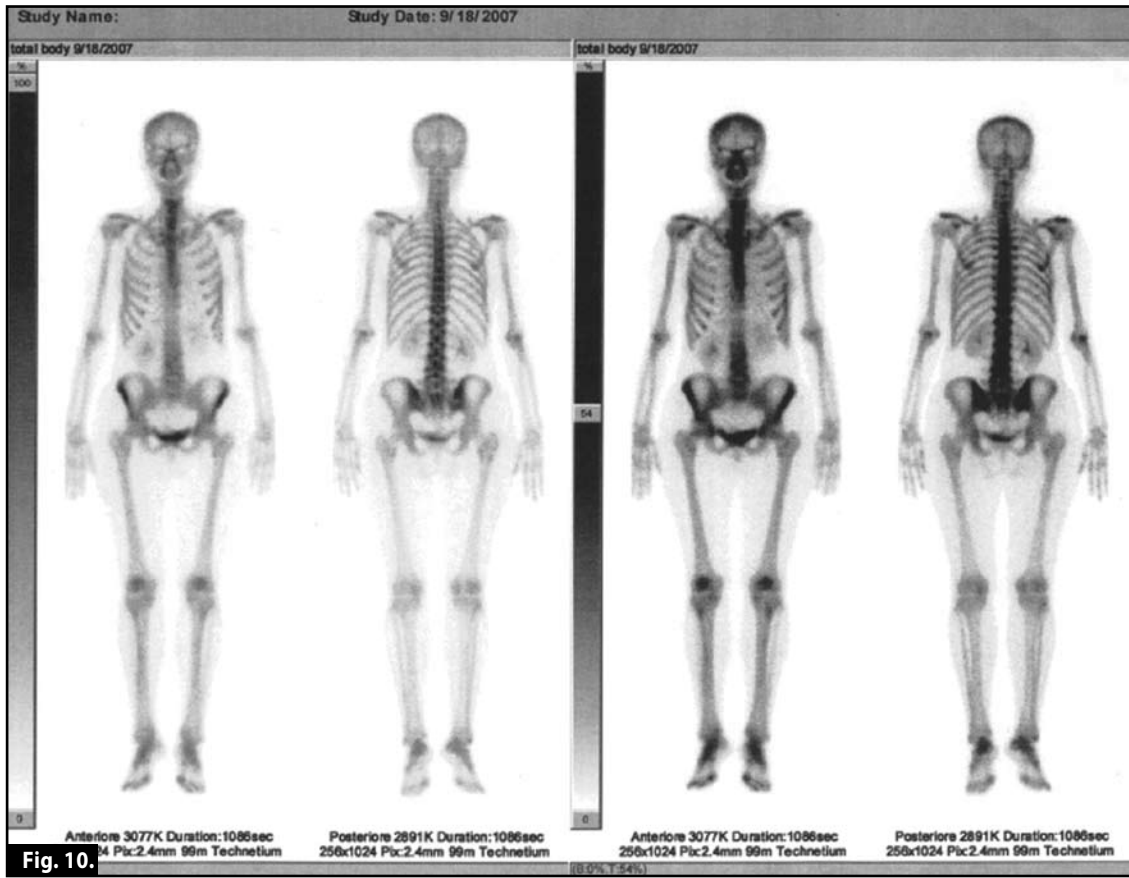


Figures 7-9: Ultrasound Scans (Feb. 15, 2006): Noticeable aspect of low-echogenicity neoplasia with strong intratumoural uptake.

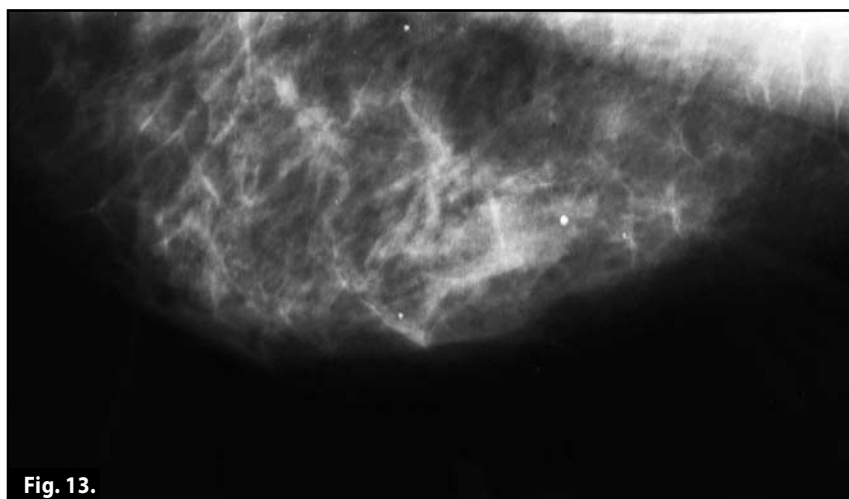
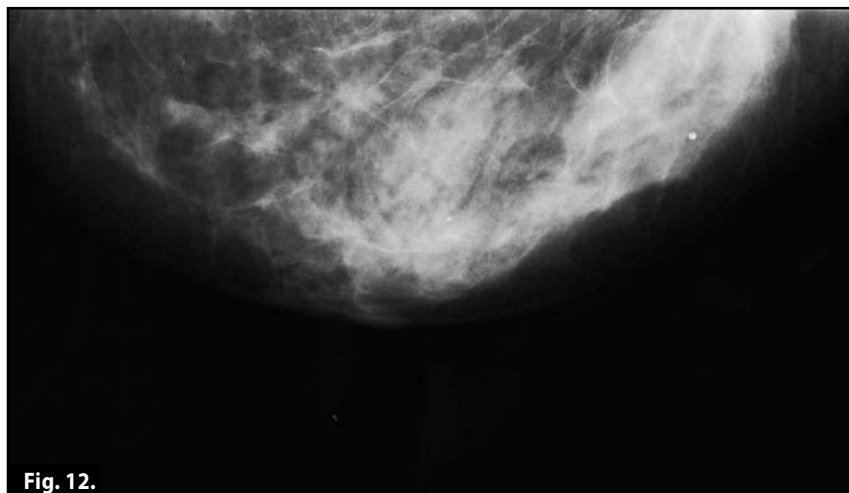
Figure 10 (next page): (Sept. 18, 2007) – Total corporeal bone and articular scintigraphy.

Figure 11 (next page): (October 12, 2007) – Positron Emission Tomography.





Figures 12-13: RX (Oct. 22, 2007)
Absence of nodular images, suspect
microcalcifications or invasive
pointers.



October 22, 2007 – Mammographic ultra-sound and X-ray were also negative and confirm remission: “breasts rich in glandular tissue with galactophorous ducts in evidence and some periareolar galactoceles without nodular images, suspected micro-calcifications, or infiltrative signs. Ultra-sound showed the presence of some cysts of maximum 5.6 mm diameter in the right breast. No solid nodular formations.” Figure 12, 13.

March 3, 2008 – Breast ultra-sound shows disappearance of neoplastic lesions, and stable result: “breasts rich in glandular tissue with galactophorous ducts in evidence and also periareolar galactoceles prevalent on the left. Scattered cysts are present in all quadrants with a maximum diameter of 3 mm but with no solid nodular images or infiltrative signs. Check-up advised in approximately 6 months.” Figure 14, 15.

RESULTS

Therapy and CLInical COURSE

The patient, after having refused a total mastectomy followed by chemo- and radiotherapy, which had been proposed by the Diagnostic Therapeutic Center for Breasts - Oncology Institute of the University of Fer-

rara (Italy), asked to be treated with the DiBella Method, which entails the synergic use of molecules with cytostatic, apoptotic, and anti-proliferative differentiating action with an increase in immune system activity and in addition, for apoptotic reasons, minimum doses (non cytotoxic, cytolytic and therefore non mutagenic) of hydroxyurea. Hydroxyurea was used as a substitute for 100 milligrams of cyclophosphamide (which is normally part of the MDB protocol) to treat the cerebral lesions of repetitive neoplastic nature in view of its ability to overcome the hematoencephalic barrier. Continuous administration of 1000 milligrams per day of hydroxyurea, over a period of approximately 10 months could have proven toxic had it not been for the concomitant administration of MLT, vitamin E, retinoids, vitamins C and D3, which effectively countered hydroxyurea toxicity. It did not cause any changes in hemopoiesis or medullary dynamics. The patient administered the therapy at home while maintaining a quality of life that allowed her to continue her intense and busy entrepreneurial activities.

1. Active Ingredients [components of the prescribed therapy (MDB)]:
Somatostatine (14 amino acids) (SST): Injected under

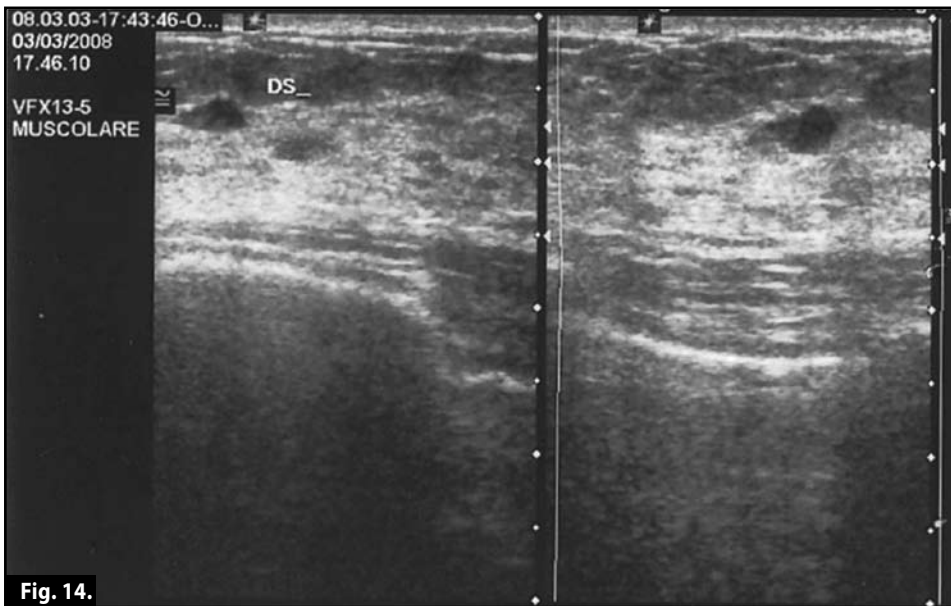


Fig. 14.

Figures 14–15: No evidence of solid nodular lesions of neoplastic nature (Mar. 03, 2008).

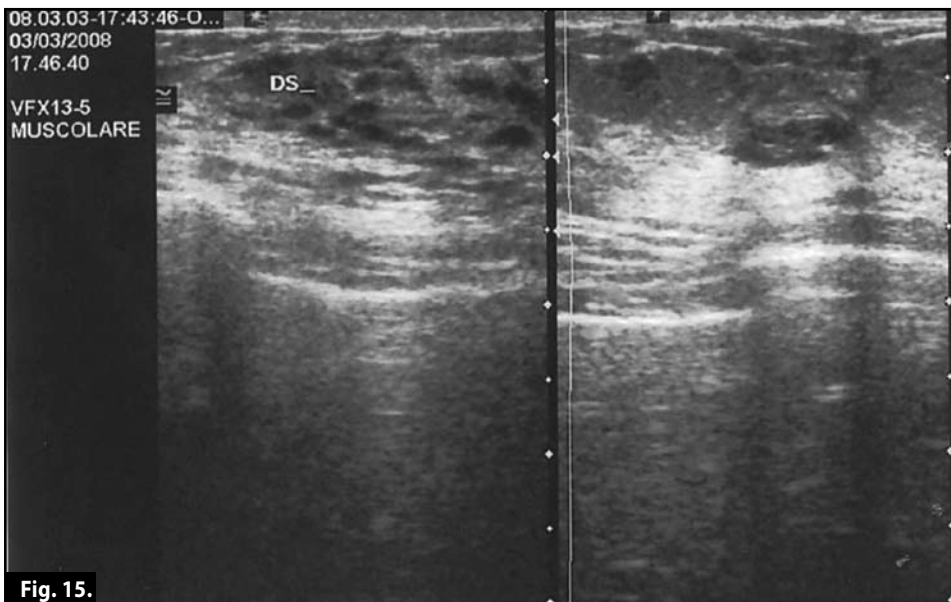


Fig. 15.

the skin at night over the space of 10 hours with a programmable infusion pump, extended infusions were necessary due to short half-life of SST (about 3 minutes) and to coincide with the nighttime peak of incretion of GH.

2. Octreotide, analogous to somatostatine (eight amino acids) and lag time formulation, 30 mg intramuscular every 25 days, for complete receptor and temporal saturation, with the same anti-proliferative and pro-apoptotic objective as somatostatine.
3. Bromocriptine 2.5 mg 1/2 tablet morning and evening to inhibit prolactin, a powerful and ubiquitous mitogenic hormone.
4. Cabergoline 1/2 tablet, 2 times a week, to reinforce the effects of bromocriptine, cabergoline also has a markedly longer half-life.
5. Vitamin solution, according to Prof. DiBella's formula: One medium spoonful (100 mg × Kg of

body weight), at least 15 minutes before eating, 3 times a day.

- i. Beta carotene 2 g
- ii. Palmitate axerophthol 1 g
- iii. All-trans retinoic acid (ATRA) 1 g
- iv. Alpha-tocopherol 1000 g
6. Dihydrotachysterol (vitamin D3 synthesis): 10 drops in the same spoon along with the vitamin compounds (i.e. 30 drops per day)
7. Chemically complexed melatonin (2 mg) with adenosine (by means of a hydrogen link) and glycine, according to Prof. DiBella's formula: 12% melatonin, 51% adenosine, and 37% glycine – 12 tablets per day
8. Anastrozole (Aromatase inhibitor) 1 mg , one tablet per day
9. Hydroxyurea – 500 mg tablet, one tablet twice a day (morning and evening) for approximately 10 months

10. Calcium 1 g, 2 times a day, taken with ascorbic acid
11. Ascorbic Acid 2 g, taken with calcium in a glass of water, 2 times a day with meals
12. Glucosamine sulfate + Galactosamine sulfate 1500 mg, 3 times a day.

Prof. Luigi DiBella's neuro-immune-endocrine biological therapy (MDB) slowly and progressively obtained a complete, objective response, without toxicity, with a mechanism of receptor differentiating apoptotic and anti-proliferative actions, with criteria, aims and mechanisms of action completely different from the usual cytotoxic and cytolytic therapy. The success of which demonstrates its ability to substitute for surgery, radiotherapy and/or chemotherapy; keeping in mind that radiotherapy and/or chemotherapy are not substitutes for surgery, but can precede and/or follow it.

In this case, due to the multifocal neoplasms (with bilateral axillary adenopathy) a surgical solution with a total mastectomy with axillary lymph node removal followed by chemo-radio therapy was planned and strongly advised by the university oncology institute, and which was subsequently refused by the patient. The objective response of MDB (Metodo DiBella) went as far as resolving both the axillary lymphadenopathy and the endocranial lesions of dubious secondary nature.

DISCUSSION

Rationale of the therapy

The loss of differentiation and proliferation, even if to different extents, are common denominators of all neoplasms. The ubiquitous receptor expression of prolactin [9, 23] and GH [32, 14] are one of the confirmations of the direct and generalized mitogenic role of this molecule.

Cellular proliferation is highly dependent on prolactin and GH, both powerful growth factors, and on GH dependent mitogenic molecules which are positively regulated by it, such as EGF, FGF, HGF, [IGF1-2, NGF, PDGF] VEGF, and TGF in addition to growth factors produced by the gastrointestinal tract, such as VIP, CCK, and PG. Both physiological as well as neoplastic cellular proliferation take place by means of these same molecules, which the neoplastic cells use to an exponential extent compared to healthy ones. Biological antidotes of GH such as somatostatine and similar compounds, reduce not only the expression and transcription of highly mitogenic growth factors, such as IGF1-2 [12, 50, 53], EGF [22], and FGF [42], but extend their negative regulation to the respective receptors with evident anti-proliferative and anti-angiogenic effects [56, 43].

The extent of the GH-IGF1 axis influence on neoplastic biological development is worth noting. The IGF1 receptors respond mitogenically to IGF. The suppressive effect of the SST and similar ones, on serum levels of IGF1, is both direct, by inhibiting the IGF1 gene, as well as indirect by suppressing GH and thus its hepatic in-

duction of IGF1. Angiogenesis is essential to neoplastic progression. Angiogenesis is in turn regulated by the fall of monocytes, interleukin 8, and by growth factors such as VEGF, TGF, IGF1, FGF, HGF, and PDGF. Each of these factors is negatively regulated by somatostatine and similar drugs [2, 5, 12, 18, 26, 59, 60, 62, 63].

The inhibition of angiogenesis induced by SST is synergistically enhanced by MLT [33, 15, 16], retinoids [40, 28, 36], vitamin D3 [29, 39], vitamin E [55, 57, 45], vitamin C [3], prolactin inhibitors [59], and components of the extra-cellular matrix [34, 47].

Likewise the cytostatic, anti-proliferative, and anti-metastatic effect of somatostatine is effectively synergized by MDB's other components:

- Retinoids [20, 61, 48, 46]
- MLT [7, 31, 41, 35, 13]
- Vitamin D3 [25, 6, 11]
- Cabergoline and bromocriptine (prolactin inhibitors) [19, 9, 33, 30, 38]
- Glucosamine sulphate, galactosamine sulphate, components of the extra-cellular matrix [51, 8]
- Vitamin E [58, 24, 37, 45, 55]
- Vitamin C [21, 44, 10]

The causal relationship between GH's receptor expression and tumor induction and progression has been shown [32], histochemically demonstrating markedly higher concentrations of GHR in tumor tissues compared to physiological tissues, thus showing the powerful mitogenic role of GH with proliferative indices depending on dose. This is direct, via receptors, as well as indirect, by inducing hepatic expression of IGF1, which is GH dependent. The GH-IGF1 axis has a decisive role in the biological behavior of many neoplasms. In a very high percentage of neoplastic cells, IGF1 receptors have been identified which respond mitogenically to the ligand. Somatostatine exerts an antitumoral effect both directly, by inhibiting the IGF1 gene's expression, as well as indirectly, by suppressing GH, which is needed for IGF1 incretion [50, 53, 54].

The SST inhibiting activity on EGF, another powerful mitogenic growth factor, with multiple mechanisms, has also been thoroughly documented:

- depending on the dosage, inhibition of tyrosine phosphorylation induced by the activation of EGFR by EGF [43];
- reduction of EGFR in tumor cells [56];
- reduction of EGF's expression [22];
- reduction of EGF's plasma concentration [12].

Mitogens produced by the gastrointestinal tract such as VIP, CCK, and PG are strongly inhibited by somatostatine and/or octreotide [27].

It has been shown that breast tumors express SSTR1, SSTR2, and SSTR3, and less frequently SSTR5 [1, 52], which in at least 50% of cases are scintigraphically visi-

ble, while in over half of the negative scintigraphs histochemical examinations revealed the presence of SSTR. Therefore the presence of SSTR [1, 4, 49, 17], and of neuro-endocrine receptors in a significant percentage of these carcinomas constitutes a further rational indication for using SST, which in any case has already been extensively justified by the above-cited negative effect of SST on GH, GH-correlated oncogenes and angiogenesis. The efficacy of somatostatine and/or octreotide is enhanced by a factorial synergic mechanism with MDB's other components. The literature thus confirms the differentiating anti-neoplastic, anti-proliferative, anti-angiogenic, and anti-metastatic action mechanisms of all MDB's components. In this case the hematochemical exams did not show any damage, but rather a progressive reduction of prolactin, estradiol, and IGF1 and maintenance of low levels of GH. The objective result, in the absence of toxicity, by progressively reducing, to disappearance, the 3 initial neoplastic lesions, the axillary adenopathy, the suspected cerebral lesions, and blockage of all metastatic dissemination, proves the effectiveness of the therapy and agrees with the positive results already published on the use of MDB on low level NHL and pulmonary carcinomas in the 3rd and 4th stages. MDB, without the need for hospitalization or even day hospitalization, in the absence of toxicity and without even a minimal reduction in the patient's daily work routine, avoided surgical trauma and the significant collateral effects of chemo- and radio-therapy.

We believe the timely use of MDB, as the first line treatment, in patients which have not been debilitated by the toxic, mutagenic, or immuno-depressive effects of chemo-radiotherapy, can greatly facilitated the results. We feel it is useful to highlight this case in order to stimulate greater interest, study, and investigation into the possibilities opened up in oncology by MDB's immuno-neuro-endocrine, biological and receptor therapy.

REFERENCES

- Albérini JL, Meunier B, Denzler B, Devillers A, Tass P, Dazord L, et al. Somatostatin receptor in breast cancer and axillary nodes: study with scintigraphy, histopathology and receptor autoradiography. *Breast Cancer Res Treat.* 2000; **61**(1): 21-32.
- Albini A, Florio T, Giunciuglio D, Masiello L, Carlone S, Corsaro A, et al. Somatostatin controls Kaposi's sarcoma tumor growth through inhibition of angiogenesis. *FASEB J.* 1999; **13**(6): 647-655.
- Ashino H, Shimamura M, Nakajima H, Dombou M, Kawanaka S, Oikawa T, et al. Novel function of ascorbic acid as an angiostatic factor. *Angiogenesis.* 2003; **6**(4): 259-269.
- Barnett P. Somatostatin and somatostatin receptor physiology. *Endocrine.* 2003; **20**(3): 255-264.
- Barrie R, Woltering EA, Hajarizadeh H, Mueller C, Ure T, Fletcher WS. Inhibition of angiogenesis by somatostatin and somatostatin-like compounds is structurally dependent. *J Surg Res.* 1993; **55**(4): 446-450.
- Barroga EF, Kadosawa T, Okumura M, Fujinaga T. Inhibitory effects of 22-oxa-calcitriol and all- trans retinoic acid on the growth of a canine osteosarcoma derived cell-line in vivo and its pulmonary metastasis in vivo. *Res Vet Sci.* 2000; **68**(1): 79-87.
- Bartsch C, Bartsch H, Buchberger A, Stieglitz A, Effenberger-Klein A, Kruse-Jarres JD, et al. Serial transplants of DMBA-induced mammary tumors in Fischer rats as a model system for human breast cancer. VI. The role of different forms of tumor-associated stress for the regulation of pineal melatonin secretion. *Oncology.* 1999; **56**(2): 169-176.
- Batra RK, Olsen JC, Hoganson DK, Caterson B, Boucher RC. Retroviral gene transfer is inhibited by chondroitin sulfate proteoglycans/glycosaminoglycans in malignant pleural effusions. *J Biol Chem.* 1997; **272**(18): 11736-43.
- Ben-Jonathan N, Liby K, McFarland M, Zinger M. Prolactin as an autocrine/paracrine growth factor in human cancer. *Trends Endocrinol Metab.* 2002; **13**(6):245-250.
- Cameron E, Pauling L, Leibovitz B. Ascorbic acid and cancer: a review. *Cancer Res.* 1979; **39**(3): 663-681.
- Campbell MJ, Gombart AF, Kwok SH, Park S, Koeffler HP. The anti-proliferative effects of 1alpha,25(OH)2D3 on breast and prostate cancer cells are associated with induction of BRCA1 gene expression. *Oncogene.* 2000; **19**(44): 5091-7.
- Cascinu S, Del Ferro E, Ligi M, Staccioli MP, Giordani P, Catalano V, et al. Inhibition of vascular endothelial growth factor by octreotide in colorectal cancer patients. *Cancer Invest.* 2001; **19**(1): 8-12.
- Cos S, Sánchez-Barceló EJ. Melatonin and mammary pathological growth. *Front Neuroendocrinol.* 2000; **21**(2): 133-170.
- De Souza I, Morgan L, Lewis UL, Raggatt PR, Salih H, Hobbs JR. Growth-hormone dependence among human breast cancers. *Lancet.* 1974; **2**(7874):182-184.
- Di Bella L, Rossi MT, Scalera G. Perspectives in pineal functions. *Prog Brain Res.* 1979; **52**: 475-478.
- Di Bella L, Gualano L. Key aspects of melatonin physiology: thirty years of research. *Neuro Endocrinol Lett.* 2006; **27**(4): 425-432.
- van Eijck CH, Kwekkeboom DJ, Krenning EP. Somatostatin receptors and breast cancer. *Q J Nucl Med.* 1998; **42**(1): 18-25.
- Florio T, Morini M, Villa V, Arena S, Corsaro A, Thellung S, et al. Somatostatin inhibits tumor angiogenesis and growth via somatostatin receptor-3-mediated regulation of endothelial nitric oxide synthase and mitogen-activated protein kinase activities. *Endocrinology.* 2003; **144**(4): 1574-1584.
- Gruszka A, Pawlikowski M, Kunert-Radek J. Anti-tumoral action of octreotide and bromocriptine on the experimental rat prolactinoma: anti-proliferative and pro-apoptotic effects. *Neuro Endocrinol Lett.* 2001; **22**(5): 343-348.
- Hassan HT, Rees J. Triple combination of retinoic acid plus actinomycin D plus dimethylformamide induces differentiation of human acute myeloid leukaemic blasts in primary culture. *Cancer Chemother Pharmacol.* 1990; **26**(1): 26-30.
- Head KA. Ascorbic acid in the prevention and treatment of cancer. *Altern Med Rev.* 1998; **3**(3): 174-186.
- Held-Feindt J, Krisch B, Mentlein R. Molecular analysis of the somatostatin receptor subtype 2 in human glioma cells. *Brain Res Mol Brain Res.* 1999; **64**(1): 101-7.
- Hooghe R, Merchav S, Gaidano G, Naessens F, Matera L. A role for growth hormone and prolactin in leukaemia and lymphoma? *Cell Mol Life Sci.* 1998; **54**(10): 1095-1101.
- Israel K, Yu W, Sanders BG, Kline K. Vitamin E succinate induces apoptosis in human prostate cancer cells: role for Fas in vitamin E succinate-triggered apoptosis. *Nutr Cancer.* 2000; **36**(1): 90-100.
- Jensen SS, Madsen MW, Lukas J, Binderup L, Bartek J. Inhibitory effects of 1alpha,25-dihydroxyvitamin D(3) on the G(1)-S phase-controlling machinery. *Mol Endocrinol.* 2001; **15**(8): 1370-1380.
- Jia WD, Xu GL, Xu RN, Sun HC, Wang L, Yu JH, et al. Octreotide acts as an antitumor angiogenesis compound and suppresses tumor growth in nude mice bearing human hepatocellular carcinoma xenografts. *J Cancer Res Clin Oncol.* 2003; **129**(6): 327-334.
- Kath R, Höffken K. The significance of somatostatin analogues in the antiproliferative treatment of carcinomas. *Recent Results Cancer Res.* 2000; **153**: 23-43.

- 28 Kini AR, Peterson LA, Tallman MS, Lingen MW. Angiogenesis in acute promyelocytic leukemia: induction by vascular endothelial growth factor and inhibition by all-trans retinoic acid. *Blood*. 2001; **97**(12): 3919-3924.
- 29 Kisker O, Onizuka S, Becker CM, Fannon M, Flynn E, D'Amato R, et al. Vitamin D binding protein-macrophage activating factor (DBP-maf) inhibits angiogenesis and tumor growth in mice. *Neoplasia*. 2003; **5**(1): 32-40.
- 30 Klijn JG, Setyono-Han B, Bontenbal M, Seynaeve C, Foekens J. Novel endocrine therapies in breast cancer. *Acta Oncol*. 1996; **35** Suppl 5: 30-37.
- 31 Kvetnoi IM, Levin IM. Melatonin and tumor growth. (In Russian with English abstract). *Eksp Onkol*. 1986; **8**(4): 11-15.
- 32 Lincoln DT, Sinowatz F, Temmim-Baker L, Baker HI, Kölle S, Waters MJ. Growth hormone receptor expression in the nucleus and cytoplasm of normal and neoplastic cells. *Histochem Cell Biol*. 1998; **109**(2): 141-159.
- 33 Lissoni P, Rovelli F, Malugani F, Bucovec R, Conti A, Maestroni GJ. Anti-angiogenic activity of melatonin in advanced cancer patients. *Neuro Endocrinol Lett*. 2001; **22**(1): 45-47.
- 34 Liu Y, Yang H, Otaka K, Takatsuki H, Sakanishi A. Effects of vascular endothelial growth factor (VEGF) and chondroitin sulfate A on human monocytic THP-1 cell migration. *Colloids Surf B Biointerfaces*. 2005; **43**(3-4): 216-220.
- 35 Maestroni GJ, Hertens E, Galli P, Conti A, Pedrinis E. Melatonin-induced T-helper cell hematopoietic cytokines resembling both interleukin-4 and dynorphin. *J Pineal Res*. 1996; **21**(3): 131-9.
- 36 Majewski S, Szmurlo A, Marczak M, Jablonska S, Bollag W. Synergistic effect of retinoids and interferon alpha on tumor-induced angiogenesis: anti-angiogenic effect on HPV-harboring tumor-cell lines. *Int J Cancer*. 1994; **57**(1): 81-85.
- 37 Malafa MP, Fokum FD, Smith L, Louis A. Inhibition of angiogenesis and promotion of melanoma dormancy by vitamin E succinate. *Ann Surg Oncol*. 2002; **9**(10): 1023-1032.
- 38 Manni A, Boucher AE, Demers LM, Harvey HA, Lipton A, Simmonds MA, et al. Endocrine effects of combined somatostatin analog and bromocriptine therapy in women with advanced breast cancer. *Breast Cancer Res Treat*. 1989; **14**(3): 289-298.
- 39 Mantell DJ, Owens PE, Bundred NJ, Mawer EB, Canfield AE. 1 alpha,25-dihydroxyvitamin D(3) inhibits angiogenesis in vitro and in vivo. *Circ Res*. 2000; **87**(3): 214-220.
- 40 McMillan K, Perepelitsyn I, Wang Z, Shapshay SM. Tumor growth inhibition and regression induced by photothermal vascular targeting and angiogenesis inhibitor retinoic acid. *Cancer Lett*. 1999; **137**(1): 35-44.
- 41 Mediavilla MD, Cos S, Sánchez-Barceló EJ. Melatonin increases p53 and p21WAF1 expression in MCF-7 human breast cancer cells in vitro. *Life Sci*. 1999; **65**(4): 415-420.
- 42 Mentlein R, Eichler O, Forstreuter F, Held-Feindt J. Somatostatin inhibits the production of vascular endothelial growth factor in human glioma cells. *Int J Cancer*. 2001; **92**(4): 545-550.
- 43 Mishima M, Yano T, Jimbo H, Yano N, Morita Y, Yoshikawa H, et al. Inhibition of human endometrial cancer cell growth in vitro and in vivo by somatostatin analog RC-160. *Am J Obstet Gynecol*. 1999; **181**(3): 583-590.
- 44 Murata A, Morishige F, Yamaguchi H. Prolongation of survival times of terminal cancer patients by administration of large doses of ascorbate. *Int J Vitam Nutr Res Suppl*. 1982; **23**: 103-113.
- 45 Neuzil J, Kagedal K, Andera L, Weber C, Brunk UT. Vitamin E analogs: a new class of multiple action agents with anti-neoplastic and anti-atherogenic activity. *Apoptosis*. 2002; **7**(2): 179-87.
- 46 Onogi N, Okuno M, Matsushima-Nishiwaki R, Fukutomi Y, Moriwaki H, Muto Y, et al. Antiproliferative effect of carotenoids on human colon cancer cells without conversion to retinoic acid. *Nutr Cancer*. 1998; **32**(1): 20-24.
- 47 Ozerdem U, Stallcup WB. Pathological angiogenesis is reduced by targeting pericytes via the NG2 proteoglycan. *Angiogenesis*. 2004; **7**(3): 269-276.
- 48 Piedrafita FJ, Pfahl M. Retinoid-induced apoptosis and Sp1 cleavage occur independently of transcription and require caspase activation. *Mol Cell Biol*. 1997; **17**(11): 6348-58.
- 49 Pinzani P, Orlando C, Raggi CC, Distante V, Valanzano R, Tricarico C, et al. Type-2 somatostatin receptor mRNA levels in breast and colon cancer determined by a quantitative RT-PCR assay based on dual label fluorogenic probe and the TaqMan technology. *Regul Pept*. 2001; **99**(2-3): 79-86.
- 50 Pollak M. The potential role of somatostatin analogues in breast cancer treatment. *Yale J Biol Med*. 1997; **70**(5-6): 535-539.
- 51 Pumphrey CY, Theus AM, Li S, Parrish RS, Sanderson RD. Neoglycans, carbodiimide-modified glycosaminoglycans: a new class of anticancer agents that inhibit cancer cell proliferation and induce apoptosis. *Cancer Res*. 2002; **62**(13): 3722-8.
- 52 Schaefer JC, Waser B, Mengod G, Reubi JC. Somatostatin receptor subtypes sst1, sst2, sst3 and sst5 expression in human pituitary, gastroentero-pancreatic and mammary tumors: comparison of mRNA analysis with receptor autoradiography. *Int J Cancer*. 1997; **70**(5): 530-537.
- 53 Schally AV, Comaru-Schally AM, Nagy A, Kovacs M, Szepeshazi K, Plonowski A, et al. Hypothalamic hormones and cancer. *Front Neuroendocrinol*. 2001; **22**(4): 248-291.
- 54 Schally AV, Nagy A. New approaches to treatment of various cancers based on cytotoxic analogs of LHRH, somatostatin and bombesin. *Life Sci*. 2003; **72**(21): 2305-20.
- 55 Shklar G, Schwartz JL. Vitamin E inhibits experimental carcinogenesis and tumour angiogenesis. *Eur J Cancer B Oral Oncol*. 1996; **32B**(2): 114-119.
- 56 Szepeshazi K, Halmos G, Schally AV, Arencibia JM, Groot K, Vadillo-Buenfil M, et al. Growth inhibition of experimental pancreatic cancers and sustained reduction in epidermal growth factor receptors during therapy with hormonal peptide analogs. *J Cancer Res Clin Oncol*. 1999; **125**(8-9): 444-452.
- 57 Tang FY, Meydani M. Green tea catechins and vitamin E inhibit angiogenesis of human microvascular endothelial cells through suppression of IL-8 production. *Nutr Cancer*. 2001; **41**(1-2): 119-125.
- 58 Turley JM, Funakoshi S, Ruscetti FW, Kasper J, Murphy WJ, Longo DL, et al. Growth inhibition and apoptosis of RL human B lymphoma cells by vitamin E succinate and retinoic acid: role for transforming growth factor beta. *Cell Growth Differ*. 1995; **6**(6): 655-663.
- 59 Turner HE, Nagy Z, Gatter KC, Esiri MM, Harris AL, Wass JA. Angiogenesis in pituitary adenomas - relationship to endocrine function, treatment and outcome. *J Endocrinol*. 2000; **165**(2): 475-481.
- 60 Vidal S, Oliveira MC, Kovacs K, Scheithauer BW, Lloyd R. Immunolocalization of vascular endothelial growth factor in the GH3 cell line. *Cell Tissue Res*. 2000; **300**(1): 83-88.
- 61 Voigt A, Hartmann P, Zintl F. Differentiation, proliferation and adhesion of human neuroblastoma cells after treatment with retinoic acid. *Cell Adhes Commun*. 2000; **7**(5): 423-440.
- 62 Watson JC, Balster DA, Gebhardt BM, O'Dorisio TM, O'Dorisio MS, Espenan GD, et al. Growing vascular endothelial cells express somatostatin subtype 2 receptors. *Br J Cancer*. 2001; **85**(2): 266-272.
- 63 Wiedermann CJ, Reinisch N, Braunsteiner H. Stimulation of monocyte chemotaxis by human growth hormone and its deactivation by somatostatin. *Blood*. 1993; **82**(3): 954-960.